

**PUBLISHED ABSTRACT**

# How Accurate is Our FAST – 1 Year Review of FAST Exam Concordance with CT Findings in Patients with Solid Organ Injury at a Level 2-Community Hospital Trauma Center

Chava Blivaiss<sup>1</sup>, N. Paul Grewal<sup>2</sup>, Ari Steiner<sup>3</sup> and Margaret Puya<sup>4</sup>

<sup>1</sup> South Nassau Communities Hospital, US

<sup>2</sup> SNCH Trauma/General Surgery, US

<sup>3</sup> SNCH Radiology, US

<sup>4</sup> SNCH Trauma, US

Corresponding author: Chava Blivaiss (Chava.blivaiss@snch.org)

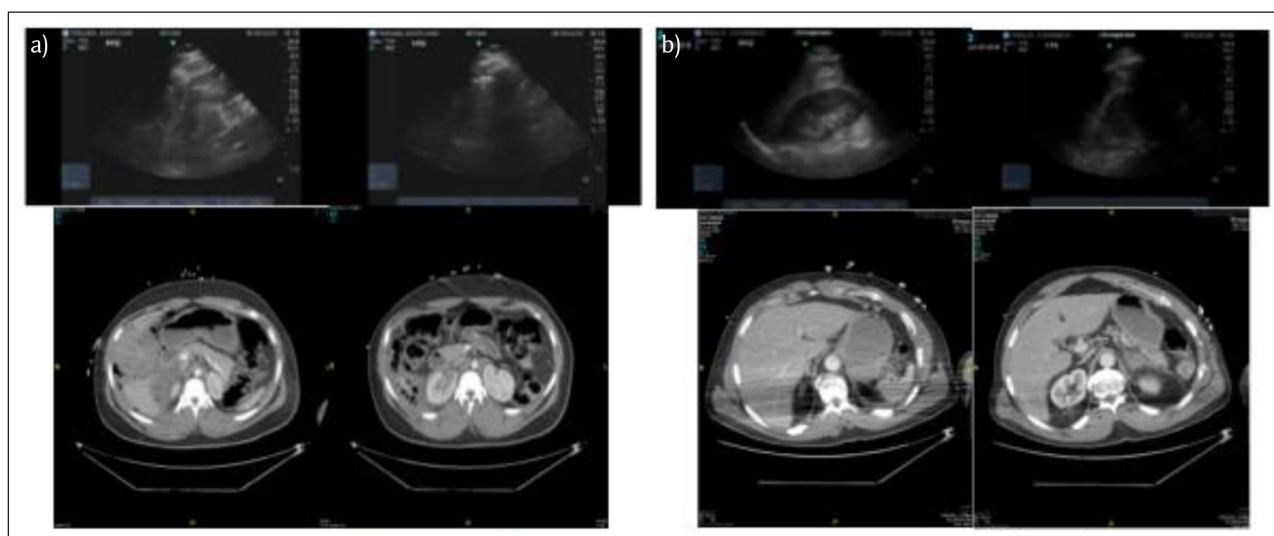
**Keywords:** Trauma; FAST; FAST concordance; Solid organ injury

## Background

Following ATLS protocols, focused assessment with sonography for trauma (FAST) is often the first diagnostic imaging modality as part of the primary survey patients with blunt trauma and generates an algorithm for the next stages in trauma triage. For those hemodynamically stable enough to tolerate further imaging, CT is performed to further evaluate organ injury. For the hemodynamically unstable patient, a positive FAST is an indication of internal hemorrhage and demands imminent intervention in the operating room. Per ACS TQIP, FAST exam has an acceptable sensitivity of 69–98% for detection of free fluid and 63% for detection of solid organ injury in adults. With such critical decision making being based on a user dependent imaging modality, we wanted to assess the accuracy and concordance of our FAST exam compared with trauma CT in patients with known solid organ injury.

## Methods

Our retrospective study was designed to evaluate the concordance of FAST exam with CT findings of solid organ injury in patients with blunt trauma between January and December 2018. A board-certified radiologist retrospectively reviewed bedside ultrasound examinations performed and interpreted by surgical residents at a level 2-trauma center, community



**Figure 1: a)** Free air in RUQ masks fluid in Morrison's pouch. **b)** Retroperitoneal bleed visualized on CT not seen on FAST.

hospital. All patients who were found to have solid organ injury were included and their CT images reviewed and compared with FAST exam images to rate concordance. Discordance was acceptable in cases where the false negative was due to FAST limitation or other confounding factors.

## Results

Of the 12 patients with solid organ injury, 3 FAST exams were accurately read as positive, 3 false negatives and 6 negatives due to FAST limitation. Concordance with CT findings was (9/12) 75%. Sensitivity was (3/6) 50%. Of the 3 false positives, 1 showed free fluid on FAST but was mischaracterized and the other 2 the quality of image was poor. All 3 false negatives involved injuries to the left upper quadrant view. Those that were considered true negatives were concordant due to limitations presented by the FAST exam. These were due to no retroperitoneal bleeding, contained hematomas or contusions, blood peripheral or anterior to spaces evaluated or body habitus/other organs interfering with exam quality.

## Discussion/Conclusions

FAST is an expedient tool for assessment of blunt trauma patients to rule out high-grade intra-abdominal injuries. However, the low overall diagnostic sensitivity of FAST may lead to underestimated injury patterns and delayed complications may occur. Of 1651 trauma activations, only 12 patients had solid organ injury, of those 9 were correctly identified on FAST exam. The average Injury Severity score for all activations was 9. Among these 12, the average ISS is 19.75 making them outliers. While our concordance rate was respectable at 75%, our sensitivity was only 50% for solid organ injury. In those that are hemodynamically stable, CT scan should be considered and the shortcomings of a negative FAST kept in mind.

**How to cite this article:** Blivaiss C, Grewal NP, Steiner A, Puya M. How Accurate is Our FAST – 1 Year Review of FAST Exam Concordance with CT Findings in Patients with Solid Organ Injury at a Level 2-Community Hospital Trauma Center. *Journal of Scientific Innovation in Medicine*. 2019; 2(2): 23. DOI: <https://doi.org/10.29024/jsim.35>

**Submitted:** 06 August 2019

**Accepted:** 06 August 2019

**Published:** 27 November 2019

**Copyright:** © 2019 The Author(s). This is an open-access article distributed under the terms of the Creative Commons Attribution 4.0 International License (CC-BY 4.0), which permits unrestricted use, distribution, and reproduction in any medium, provided the original author and source are credited. See <http://creativecommons.org/licenses/by/4.0/>.

