

A New Technique for Mastopexy and Reduction Mammoplasty: The Rolling Bilateral Flap Technique

Stefano A. Karoschitz

Società Italiana di Chirurgia Plastica Ricostruttiva ed Estetica (SICPRE), Rome, Italy
Email: rejeunesse@gmail.com

Received 29 February 2016; accepted 4 April 2016; published 8 April 2016

Copyright © 2016 by author and Scientific Research Publishing Inc.
This work is licensed under the Creative Commons Attribution International License (CC BY).
<http://creativecommons.org/licenses/by/4.0/>



Open Access

Abstract

Background: Numerous techniques have been proposed as “gold standard” for mastopexy, as for reduction mammoplasty. The quality of the breast parenchyma should be a primary factor in selecting the most appropriate technique for an individual case. **Objective:** The article describes a simple technique that can be used either for mastopexy or for reduction mammoplasty, giving optimal breast shape and position. It is appropriate for patients having some degree of ptosis, and especially for those in whom the glandular component of the breast predominates. **Methods:** The technique entails elevating the entire dome of the breast, rolling it under, and then stitching the two halves of the breast parenchyma together (lateral and medial dermoglandular flaps), while the upper pedicle (a third dermoglandular flap) bearing the nipple areolar complex (NAC) severed from the two inferior flaps is attached as a cap. The result is a new and attractive shape of the underlying supporting “barrel”. The technique can be performed with the T scar or the vertical scar approach. **Results:** The procedure was applied for various indications on 45 patients aged 20 - 62 years. Good results were only achieved in 36 women with predominant glandular component. Nine patients with fatty breasts achieved unsatisfactory results (6 with T scar, 3 with vertical scar) and very poor breast projection. **Conclusions:** The best-suited candidates for the proposed technique for mastopexy or reduction mammoplasty are women in whom the glandular component of the breast predominates. This simple technique, applicable with either inverted T scar or vertical scar approaches, carries very low morbidity, affording an attractive profile, long-lasting results, and conserving the patient’s ability to breast feed.

Keywords

Mastopexy, Reduction Mammoplasty, Mammoplasty, Inverted T Scar, Vertical Scar, Breast Autologous Prosthesis, Gigantomastia, Breast Asymmetry, NAC Pedicle

1. Introduction

A mammoplasty that is not of the additive type almost always entails some reduction of the breast volume; such a reduction, of almost one size, occurs in the pure mastopexy [1]. Conversely, in reduction mammoplasty, a larger volume is excised, depending on the patient's demands and requirements. However, in both interventions, the aim of plastic surgery is to give the breast a new and attractive shape such as to meet the patient's requests.

The importance of properly evaluating the mammary breast components prior to selecting the surgical technique is well established; however, it is frequently underestimated. Fat, skin, and mammary gland combine to define the breast tissues, and thus the shape of the breast. Their percentage and quality vary widely among the female population [2] [3]. Fat and mammary gland are the most important components of the breast parenchymal tissue; in a technical metaphor, the gland could be compared to a rock, and the fatty tissue to a liquid mass. Thus, in a mammoplasty without implant, the larger the glandular component is, the higher will be the projection of the breast; further, the outcome of surgery will be longer-lasting. Skin having a thick derma will also contribute to a durable result.

The breast is neither a cone nor a truncated cone, nor yet a hemisphere. In nature, the true shape of the breast is a dome, an architectural structure defined, mathematically, by a complex equation; it differs greatly from the diagrammatic representations frequently found in the literature [3].

The proposed technique, applicable with either the inverted T scar or the vertical scar approaches, offers elevation and projection of the breast, maintaining each sector of the dome (base and tip) at its appropriate level, without altering the proper fit of the breast onto the trunk.

2. Patients and Methods

The technique was first attempted in 2000, in a 32-year-old woman with asymmetric gigantomastia and a very predominant glandular breast component. The procedure was subsequently applied for various indications in a further 45 women aged 20 to 62 (in the majority of cases (29/45) using the inverted T scar approach, but in 16/45 cases the vertical scar approach). The technique is indicated for women with glandular breast predominance.

3. The Rolling Bilateral Flap Technique

This technique offers two advantages. The ptotic parenchyma is first lifted and reshaped into a new and attractive profile (**Figure 1**), after which excess breast volume, if any, may be reduced. In this approach, mastopexy (**Figure 2(a)**, **Figure 2(c)**) and reduction mammoplasty (**Figure 2(b)**, **Figure 2(d)**) have two surgical stages in common: sculpting the NAC pedicle, and the "rolling stage", during which the bilateral dermoglandular flaps of the base of the breast are rolled upon themselves (**Figure 3**). Conversely, during reduction mammoplasty, the rolling stage is preceded by the reduction stage, in which two edges of the parenchyma (one sagittal and the other horizontal; **Figure 2(b)**, **Figure 2(d)**) are excised to provide the desired reduction in breast volume.

The technique begins by sculpting a superior NAC dermoglandular pedicle, which is separated from the underlying parenchyma. For mastopexy, the rolling stage then follows, in which the inferior parenchymal complex (**Figure 3**) is bisected into two bilateral flaps, each of which is then rolled around an axis corresponding to the predicted projection axis of the new breast. The two rolled flaps are then stitched together into a compact cylindrical glandular mass, which will comprise an autologous prosthesis forming the new breast; it is repositioned at a higher suprafascial reticular space.

4. Preoperative Marking

The patient is seated or standing [2]-[9]. For either the inverted T or the vertical scar approach, the point around which reshaping of the breast begins is the new localization of the nipple areolar complex (NAC) [10]-[13]. The new location of the NAC depends on several factors (dimensions of thoracic cage, breast mass, patient's height, etc.) but on average it is $\cong 19$ cm from the jugulo-sternal notch, or from the clavicular first third (the clavicular line crossing the nipple) [2] [8] [9]. However, in the present technique it is marked by taking the mid-point through the 19 cm points (**Figure 4(a)**) of the two thoracic lines, which reach the nipple, respectively, from the jugulo-sternal notch and from the clavicular first medial third. The position may be confirmed by projecting the apparent mid-point of the inframammary fold onto the upper pole of the breast, placing the thumb in opposition

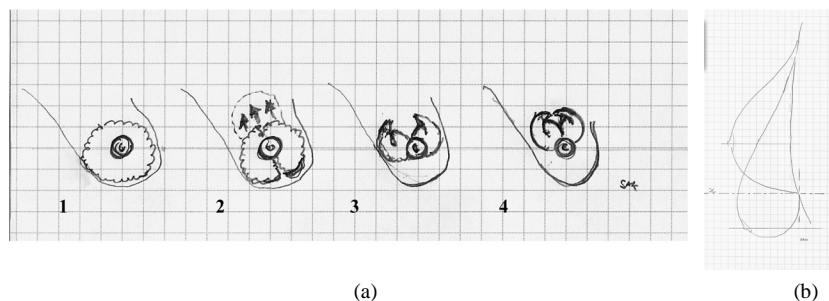


Figure 1. Diagram showing the maneuvers and goals of the technique. (a) The steps involved in remolding the parenchyma: (1-2) sagittal severing of the parenchyma and blunt dissection of the cephalad space, after which (3) the two parenchymal halves are rolled inwards, and (4) sutured together while pulling up the gland. (b) Goals of the technique.

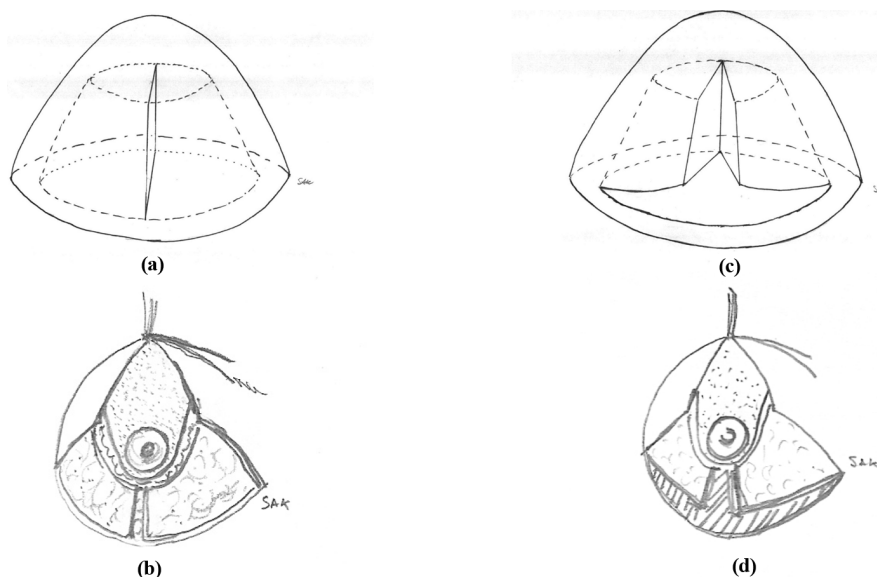


Figure 2. (a)-(b) First stage of mastopexy; (a) Diagram of the breast dome showing the bisected parenchyma; (b) De-epithelization of the marked area for the NAC pedicle and for the two bilateral flaps, as first step of the rolling bilateral flap technique for mastopexy when surgery is to finish with an inverted T scar. (c)-(d) First stage of reduction mammoplasty; (c) Diagram of the breast dome and of the bisected parenchyma after orthogonal wedges have been cut away; (d) First stage of the rolling bilateral flap technique for reductive mammoplasty when surgery is to finish with an inverted T scar: the marked area is de-epithelized, the superior pedicle is sculpted, and the two (orthogonal) wedges of the parenchyma are excised.

to the index finger of the hand, closed upon the ptotic breast [4] [5] [7] [8] [12] [14]. Then, if choosing the inverted T approach, (Figure 4(b)), two points (B and C) are located laterally to the areola (on a virtual line crossing the NAC), corresponding to the planned mid-inframammary fold. In general, AB and AC are approximately 5.5/6 cm in length [4] [5] [7] [14]. The areolar diameter should be fixed at $3.5 \geq \emptyset \leq 4$ cm. The inframammary fold is marked with arms raised. The medial and lateral limits of the inframammary incision (Figure 4(c)) are marked at the points where the overhanging fold of breast tissue disappears; the new inframammary fold will thus be concealed by the overhanging breast tissue [9] [13].

5. Operative Technique

The basic principles of the rolling bilateral flap technique (Figure 3) comprise sculpting a higher pedicle with the NAC, and lifting the breast complex, bisecting it into two halves, then rolling each half and suturing the two halves together at a higher position. This new “glandular barrel” provides projection, while the NAC pedicle gives shape to the top of the breast dome. Conversely, in reduction mammoplasty, two perpendicular wedges are

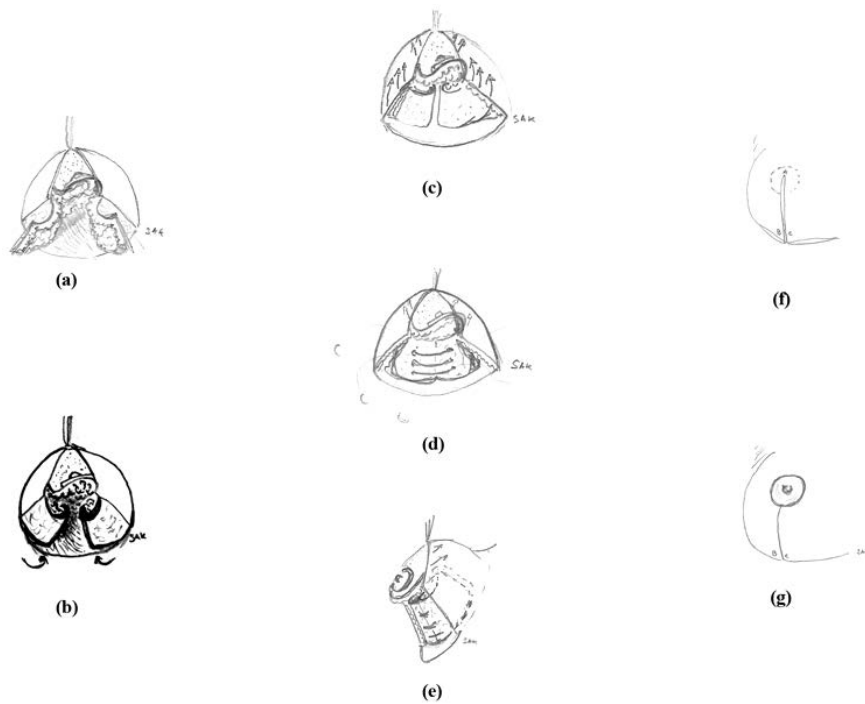


Figure 3. (a)-(f) The rolling stage: successive steps common to both approaches of the technique when finishing with an inverted T scar. (a) The upper pedicle and two bilateral flaps of the parenchyma are sculpted. (b) The two bilateral dermoglandular flaps are rolled under. (c) Subcutaneous scissors are used to undermine just sufficiently to mobilize the upper pedicle together with the NAC and the two halves of the gland, after which the cephalad space is bluntly undermined. (d)-(e) The rolling stage is stabilized, by suturing together the two rolls of tissue to form a “barrel”. (f)-(g) Skin closure is achieved, while the NAC is brought outside.

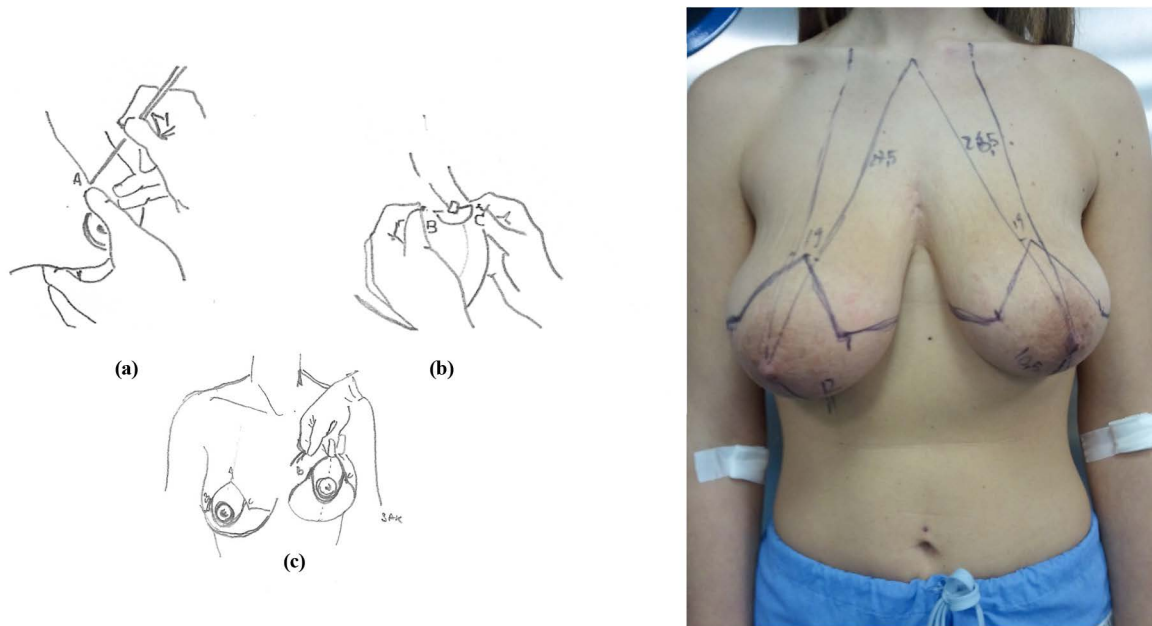


Figure 4. (a)-(c) Steps in preoperative breast marking, when surgery is to finish with an inverted T scar. (a) Fixing the new NAC at A, just medially to the first third clavicular line. (b) B-C indicate the two points which will close the new breast on the inframammary mid-point. (c) The two points B and C reach the inframammary marking just where it disappears as a fold; design of the upper pedicle with the NAC.

excised at the center of the parenchyma and carefully removed (**Figure 2(b)**, **Figure 2(d)**). Whereas simple mastopexy results in an average decrease of one brassiere cup size [15], in the case of reduction mammoplasty, the surgeon must use his/her skill and experience to calculate the correct parenchymal reduction (the size of the two perpendicular wedges) that will meet the patient's requirements.

The first stage of surgery comprises the de-epithelialization of the entire marked zone (**Figure 2**). Blade de-epithelialization is recommended for the NAC pedicle, and scissors de-epithelialization for the remainder of the area.

The dermoglandular NAC flap is separated from the underlying parenchyma. In mastopexy, the parenchyma complex is bisected sagittally (**Figure 2(a)**, **Figure 2(c)**); in reduction mammoplasty a sagittal wedge of the trunk of the dome is excised, and likewise a horizontal wedge of the base of the dome (**Figure 2(b)**, **Figure 2(d)**).

The reticular suprafascial virtual space in the upper pole of the pectoral zone is now undermined, to enable the new barrel complex to slide above it (**Figure 1(a)**). The undermining continues upwards and laterally from the marked line, following a plane that is just subcutaneous, only for the width necessary to mobilize the two dermoglandular flaps and the dermoglandular NAC pedicle (**Figures 3(c)-(d)**).

At this point, the remaining two glandular portions are rotated inwards, lifted and sutured together so as to comprise a single block occupying the upper pectoral zone (**Figure 3(e)**). Preferable at least 3 - 4 stitches in braided 2/0 suture thread should be placed. This maneuver alone pulls up the entire parenchyma. The entire dome is closed by the skin, after which the NAC can be externalized, using a $3.5 \geq$ areolotome diameter ≤ 4 cm (**Figures 3(f)-(g)**). The author does not personally recommend fixing anchorage stitches onto the pectoral fascia, since this maneuver generally increases bleeding complications, and offers few temporary advantages, without improving the long-term result.

6. Results

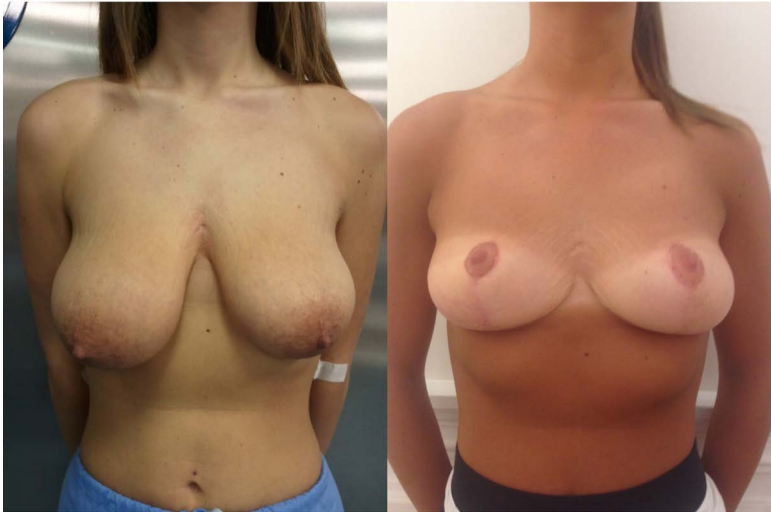
The outcome was only satisfactory in 36 cases; of these, 23 patients were treated with the T scar approach, and 13 with the vertical scar approach. In the remaining 9 patients (6 of whom were treated via the T scar approach, 3 via the vertical scar approach), the projection achieved was unsatisfactory; in all these cases, fat was the predominant breast tissue. Cases with glandular predominance in the breast were those achieving the best result in terms of breast shape. The glandular component was found to offer valid support to the projection of the breast "dome", whereas fatty tissue does not provide adequate shape.

No early postoperative complications, including hematoma or infections, occurred in any patient. At one month postoperatively, the breast achieved its definitive shape. Unsatisfactory breast projection occurred in all patients with fatty tissue predominance in the breast parenchyma. In all patients with glandular predominance, after 1 year the breast shape had regained its attractive projection. Morbidity or impairment of NAC sensitivity did not occur; necrosis did not occur in any case, and nor was scar revision necessary. Mastopexy alone lead to an average decrease of one brassiere cup size in patients with glandular predominance; the reduction was more marked in patients with fatty tissue predominance, in agreement with other reports [1] [16]. Importantly, the ability to breast feed was conserved.

Figures 4-7 illustrate the case of a young woman of 24, with good glandular predominance, and breast asymmetry with significant ptosis. The right breast was larger; reduction mammoplasty was applied, with excision of 200 gr of parenchymal tissue; the left breast underwent mastopexy alone. The T scar approach was applied in this case, being more appropriate when significant breast tissue must be removed. It is possible that a better outcome (with less scarring) might have been achieved with the vertical scar approach. However, the skin is often loose and with numerous striae in young subjects with a high glandular component [2]; the removal of a larger area of skin offers the best reshaping, since the relative lack of elasticity means that many "defects" are eliminated [12] [13] [16] [17].

7. Discussion

Since 1990, the author has worked in this field, applying several techniques, in particular: Ribeiro's [3] [7], Skoog's [6] (especially the medial evolution), Arié-Pitanguy's [4] [5] [8], Passot's [2] [18], Bankoff-Lassus's [9] [10], and Benelli's [19]. Total cases treated amount to some 800 patients; indications have been to pure mastopexy and to pure reductive mammoplasty (for aesthetic or oncological reasons). During this time it has become



(a) (b)

Figure 5. Frontal view, preoperatively (a), and 10 months postoperatively (b), of a case in which the rolling bilateral flap technique was used in reductive mammoplasty, by 200 gr, at the right breast, with mastopexy alone at the left breast.

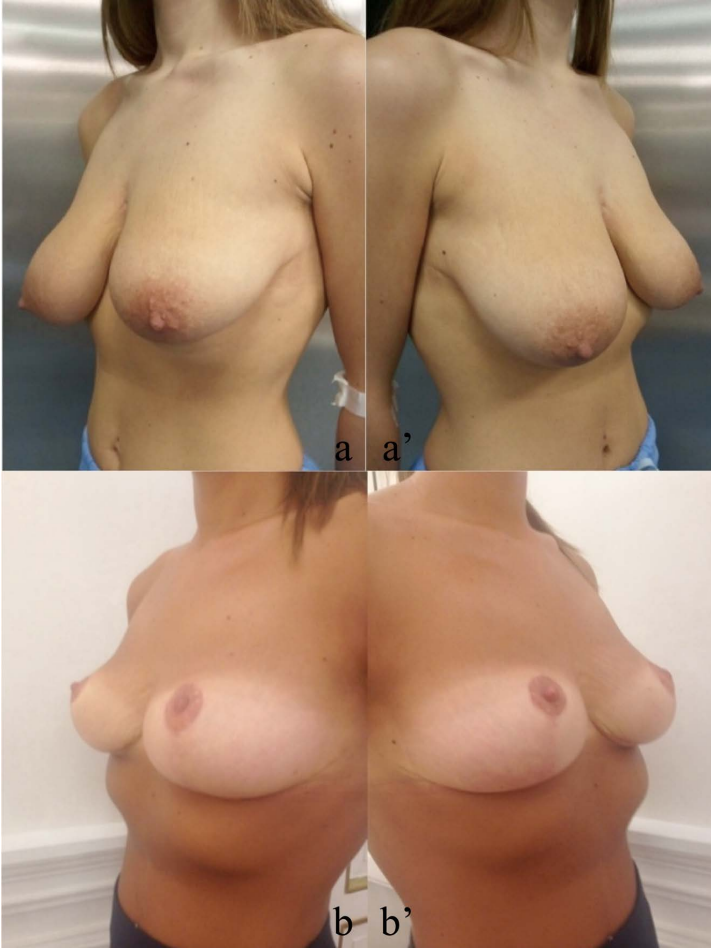


Figure 6. (a-a'-b-b'); Oblique view of the same case as **Figure 5**.

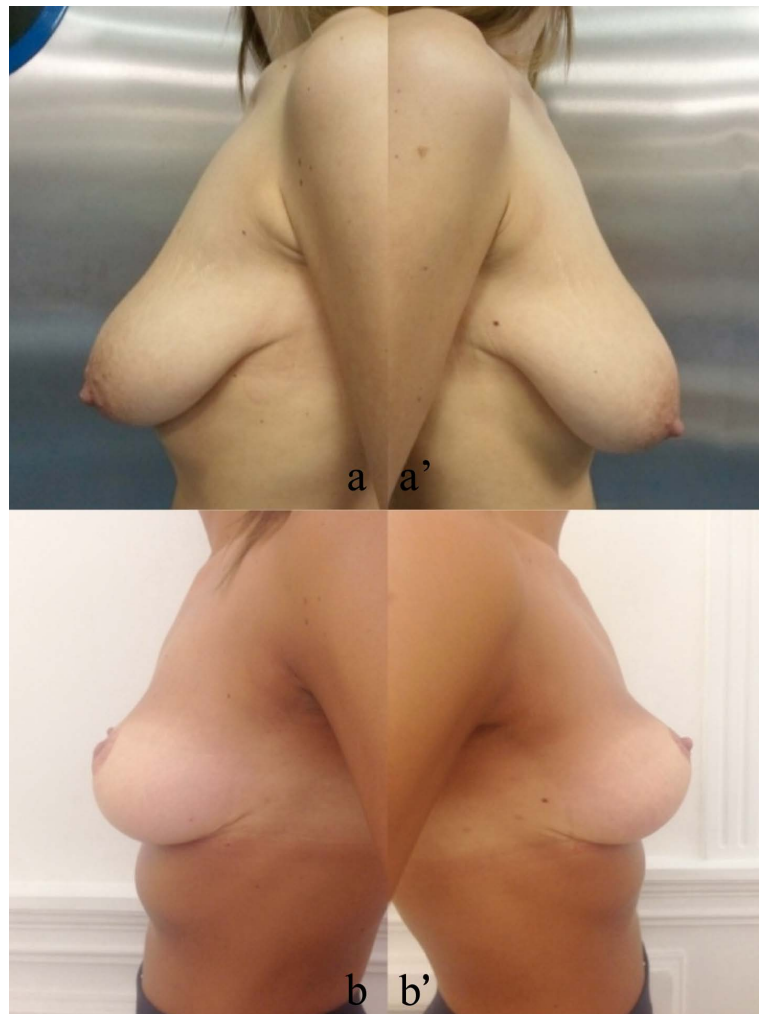


Figure 7. (a-a'-b-b'); Lateral view of case in Figure 5.

progressively clear that two elements (apart from the surgeon's manual skill) are required to obtain good results: a technique with a minimally-invasive approach, and a favorable good parenchyma.

Two approaches now dominate all techniques of mammoplasty in which implant neoaugmentation is not required: an approach in which the external scar is fundamental, and an approach paying more attention to the parenchymal architecture. It is not possible to build an architectural structure like a dome, and then subject it to lateral gravitational forces, to which the breast is continually subjected, without considering the importance of a projecting support. Thus, in the breast, attention must not be limited to the drape design without considering the importance of the structure of the parenchyma [14] and its rearrangement. From Peixoto to Benelli and Nahas, the Bilateral Crossed Flaps Technique [14] [15] [19]-[22] has attempted to provide good projection to the breast shape, through a procedure that is perhaps a little more difficult than the technique proposed here, and that suffers from the same limitations.

When a woman asks her surgeon for "new sexy breasts" and her choice is for a pure mastopexy or a reduction mammoplasty, the inverted T scar or the vertical scar are the only techniques that can offer the best reshaping and projection of the breast [12] [13] [16] [17]. Thus theoretically Passot's technique might be the best approach to mastopexy, if the glandular component were the only determinant for better breast projection. However, the flat texture of the skin-flap employed to cover the parenchyma tends to depress the entire dome [2] [18]. Unfortunately, Benelli's technique also pushes down the dome, and provides a solution with limited scarring, which is only efficacious for very light breasts [16] [19]. Conversely, Ribeiro's technique is an excellent solution that is successful on both parenchymal tissue and skin, and gives new projection even to a flattened and empty breast;

it possibly loses some of its efficacy in the case of larger cup sizes [3] [7].

8. Conclusions

The “rock-like” property of the glandular component of the parenchyma influences all mammoplasty techniques: greater gland preponderance leads to more satisfactory breast projection.

The technique presented here may provide an easy solution and simplify the approach to mammoplasty. However, there are numerous valid techniques enabling the surgeon to satisfy patients with varied requirements. The article draws attention to the need for proper evaluation of the breast parenchyma so that the best approach for each individual patient may be selected, leading to a healthy and long-lasting outcome.

Conflict of Interest Statement

The author declares that he has no conflicts of interest to disclose.

References

- [1] Weichman, K., Dofl, M. and Matarasso, A. (2014) The Impact of Mastopexy on Brassiere Cup Size. *Plastic & Reconstructive Surgery*, **134**, 34e-40e. <http://dx.doi.org/10.1097/PRS.0000000000000288>
- [2] Galtier, M. (1955) *Chirurgie Esthétique Mammaire*. Ed. G. Doin & C, Paris.
- [3] Ribeiro, L. (1989) *Cirurgia Plastica da Mama*. Ed. MEDSI, Rio de Janeiro.
- [4] Arié, G. (1957) Una nueva técnica de mastoplastia. *Rev Latinoam Cir Plast*, **3**, 23-31.
- [5] Pitanguy, I. (1961) Mammoplasty. Study of 245 Consecutive Cases and Presentation of a Personal Technique. *Revista Brasileira de Cirurgia*, **42**, 201-220.
- [6] Skoog, T. (1963) A Technique of Breast Reduction: Transposition of the Nipple on a Cutaneous Vascular Pedicle. *Acta Chirurgica Scandinavica*, **126**, 453-465.
- [7] Ribeiro, L. (1975) A New Technique for Reduction Mammoplasty. *Plastic & Reconstructive Surgery*, **55**, 330-334. <http://dx.doi.org/10.1097/00006534-197555030-00010>
- [8] Rees, T.D. (1980) *Aesthetic Plastic Surgery*. Ed. W.B. Saunders Company, Philadelphia.
- [9] Bostwick, J. (1990) *Plastic and Reconstructive Breast Surgery* Ed. QMP, St. Louis.
- [10] Bankoff, G. (1959) A New Simplified Method of Mammoplasty. *California Medicine*, **90**, 349-352.
- [11] Lassus, C. (1996) A 30-Year Experience with Vertical Mammoplasty. *Plastic & Reconstructive Surgery*, **97**, 373-380. <http://dx.doi.org/10.1097/00006534-199602000-00015>
- [12] Dex, E.A., Asplund, O., Ardehali, B. and Eccles, S.J. (2008) A Method to Select Patients for Vertical Scar or Inverted-T Pattern Breast Reduction. *Journal of Plastic, Reconstructive & Aesthetic Surgery*, **61**, 1294-1302. <http://dx.doi.org/10.1016/j.bjps.2007.09.013>
- [13] Tebbet, J.B. (2013) A Process for Quantifying Aesthetic and Functional Breast Surgery: I. Quantifying Optimal Nipple Position and Vertical and Horizontal Skin Excess for Mastopexy and Breast Reduction. *Plastic & Reconstructive Surgery*, **132**, 65-73. <http://dx.doi.org/10.1097/PRS.0b013e3182910b0a>
- [14] Peixoto, G. (1980) Reduction Mammoplasty: A Personal Technique. *Plastic & Reconstructive Surgery*, **65**, 217-225. <http://dx.doi.org/10.1097/00006534-198002000-00015>
- [15] Gheita, A. and Moftah, A. (2011) Breast Ptosis Managed by Mastopexy Using the Triple Flaps Procedure. *Aesthetic Plastic Surgery*, **35**, 107-115. <http://dx.doi.org/10.1007/s00266-010-9545-3>
- [16] Hidalgo, D.A. and Spector, J.A. (2013) Mastopexy. *Plastic & Reconstructive Surgery*, **132**, 642e-656e. <http://dx.doi.org/10.1097/PRS.0b013e31829fe4b4>
- [17] Swanson, E. (2013) Prospective Comparative Clinical Evaluation of 784 Consecutive Cases of Breast Augmentation and Vertical Mammoplasty, Performed Individually and in Combination. *Plastic & Reconstructive Surgery*, **132**, 30e-45e. <http://dx.doi.org/10.1097/PRS.0b013e3182910b2e>
- [18] Passot, R. (1925) La correction esthétique du prolapsus mammaire par le procédé de transposition du mamelon. *Presse Medicale*, **33**, 317.
- [19] Benelli, L. (1990) A New Periareolar Mammoplasty. The “Round Block” Technique. *Aesthetic Plastic Surgery*, **14**, 93-100. <http://dx.doi.org/10.1007/BF01578332>
- [20] de la Plaza, R., de la Cruz, L., Moreno, C. and Soto, L. (2004) The Crossed Dermal Flaps Technique for Breast Reduction. *Aesthetic Plastic Surgery*, **28**, 383-392. <http://dx.doi.org/10.1007/s00266-004-0370-4>

- [21] Gargano, F., Tessier, P. and Wolfe, A.S. (2011) Breast Reduction with Dermoglandular Flaps: Tessier's "Total Dermo-Mastopexy" and the "Yin-Yang Technique". *Annals of Plastic Surgery*, 67, S42-S54.
- [22] Nahas, F.X. and Ferreira, L.M. (2012) Mastoplastia com Retalhos glandulares Cruzados. In: Ribeiro, R.C. and Saltz, R., Eds., *Cirurgia da Mama: Estetica e Reonstrutora*, 2nd Edition, Revinter, Rio de Janeiro, 487-493.