



Comparison of Postoperative Analgesia between a Femoral Nerve Block with Local Infiltration Analgesia and a Suprainguinal Fascia Iliaca Compartment Block with Local Infiltration Analgesia for Total Hip Arthroplasty: A Prospective, Randomized, Open Label Trial

Shigehiko Urabe ^a, Yoshiaki Terao ^{a*}, Yuki Soejima ^a,
Hiroki Iwanaga ^a, Natsuko Oji ^a, Makito Oji ^a
and Tetsuya Hara ^b

^a Department of Anesthesia, Nagasaki Rosai Hospital 2-12-5 Setogoe, Sasebo 857-0134, Japan.

^b Department of Anesthesiology and Intensive Care Medicine, Nagasaki University Graduate School of Biomedical Sciences, 1-7-1 Sakamoto, Nagasaki 852-8501, Japan.

Authors' contributions

This work was carried out in collaboration among all authors. Authors SU, YT and HI prepared the manuscript. Authors YS, NO and MO collected the clinical data. Author SU prepared the draft of the manuscript, and analyzed the data. Author TH revised the manuscript. All authors read and approved the final manuscript.

Article Information

DOI: <https://doi.org/10.9734/jammr/2024/v36i85530>

Open Peer Review History:

This journal follows the Advanced Open Peer Review policy. Identity of the Reviewers, Editor(s) and additional Reviewers, peer review comments, different versions of the manuscript, comments of the editors, etc are available here: <https://www.sdiarticle5.com/review-history/120289>

*Corresponding author: E-mail: yoterao@nagasaki.johas.go.jp;

Cite as: Urabe, Shigehiko, Yoshiaki Terao, Yuki Soejima, Hiroki Iwanaga, Natsuko Oji, Makito Oji, and Tetsuya Hara. 2024. "Comparison of Postoperative Analgesia Between a Femoral Nerve Block With Local Infiltration Analgesia and a Suprainguinal Fascia Iliaca Compartment Block With Local Infiltration Analgesia for Total Hip Arthroplasty: A Prospective, Randomized, Open Label Trial". *Journal of Advances in Medicine and Medical Research* 36 (8):100-107. <https://doi.org/10.9734/jammr/2024/v36i85530>.

ABSTRACT

Aims: This study aimed to compare the analgesic efficacy between a suprainguinal fascia iliaca compartment (SFIC) block with local infiltration analgesia (LIA) and a femoral nerve (FN) block with LIA in patients who underwent total hip arthroplasty (THA).

Study Design: Prospective, randomized, open-label trial.

Place and Duration of Study: Department of Anesthesia, Nagasaki Rosai Hospital, Sasebo, Japan between May 2023 and March 2024.

Methodology: A total of 50 patients who underwent THA under total intravenous anesthesia using propofol were included in this study. The patients were randomly divided into two groups: Group F (n=25), which received an ultrasound-guided FN block with 30 mL of 0.25% levobupivacaine and Group S (n= 25), which received an ultrasound-guided SFIC block with 30 mL of 0.25% levobupivacaine. After fascial closure, both groups were administered 20 mL of 0.25% levobupivacaine on the incision line. All patients received 1000 mg intravenous acetaminophen prior to the end of the operation and at 6, 12, 18, and 24 h after the operation, and in those who needed it, diclofenac sodium 50 mg was used as a rescue analgesic. The nursing staff evaluated the postoperative pain using a numerical rating scale (NRS) at rest at 0, 1, 3, 6, 12, 18, and 24 h postoperatively and the number of analgesic requirements postoperatively.

Results: No significant differences were found between the two groups in terms of patient characteristics, except for the intraoperative fluid balance (1020 (783-1115) vs. 680 (570-980) mL, $P = .01$). Moreover, during the study period, no significant differences were observed between the two groups in the NRS scores ($P = .25$) and the number of rescue analgesic requirements ($P = 1.0$).

Conclusion: Both the FN block with LIA and SFIC block with LIA would have an equivalent adjunctive analgesic effect after THA.

Keywords: Total hip arthroplasty; femoral nerve block; suprainguinal fascia iliaca compartment block; local infiltration analgesia; obturator nerve block; postoperative pain.

ABBREVIATIONS

FN	: Femoral Nerve
ON	: Obturator Nerve
LFCN	: Lateral Femoral Cutaneous Nerve
FIC	: Fascia Iliac Compartment
IFIC	: Infrainguinal Fascia Iliac Compartment
SFIC	: Suprainguinal Fascia Iliac Compartment
PENG	: PEricapsular Nerve Group
THA	: Total Hip Arthroplasty
LIA	: Local Infiltration Analgesia
NRS	: Numerical Rating Scale
TCI	: Target-Controlled Infusion
ANOVA	: ANalysis Of VAriance
ASA	: American Society of Anesthesiologists

1. INTRODUCTION

Numerous analgesic techniques have been employed for pain management after total hip arthroplasty (THA). However, there is no gold standard for this procedure yet, and finding optimal analgesic technique is needed.

“We previously reported that the lateral femoral cutaneous nerve (LFCN) block combined with the femoral nerve (FN) block is effective for postoperative pain during the early postoperative period after THA” [1]. However, the high rate of block failure secondary to anatomic variations in the LFCN course limits the recommendations of

the LFCN block as part of the standard analgesic treatment [2].

Our previous study demonstrated that an LFCN block with an FN block and local infiltration analgesia (LIA) with an FN block would have the equivalent adjunctive analgesic effect after THA [3]. Jiménez-Almonte et al. described the use of LIA as an alternative to peripheral nerve blocks as an analgesic intervention after THA. They also described that LIA has been shown to be a cost-effective treatment option compared with peripheral nerve blocks [4]. According to these studies, our institution has since used LIA with an FN block as the first choice for postoperative analgesia after THA.

Dolan et al. described that the ultrasound-guided infrainguinal fascia iliac compartment (IFIC) block led to a significant loss of sensation in the LFCN, FN, and obturator nerve (ON) innervation areas. However, the evidence of ON blockade provided by the IFIC block remains limited [5,6]. In patients with femoral neck fractures, Liang Y et al. described that an FN block and an IFIC block provide similar analgesic effects [7]. Conversely, Xiao-dan Li et al. elucidated that compared to an IFIC block, an FN block decreased the pain scores at 24 h at rest in patients undergoing hip and proximal femur surgery postoperatively [8].

Hebbard et al. first reported “an ultrasound-guided longitudinal suprainguinal fascia iliaca compartment (SFIC) block” [9]. Furthermore, Vermeylen et al. described that “an SFIC block produces a more complete sensory block of the medial, anterior, and lateral region of the thigh, compared with an IFIC block” [6]. Thus, the SFIC block has the potential to cover pain in the FN- and LFCN-innervated areas including ON-innervated areas with a high probability than the IFIC block. Hence, we hypothesized that the analgesic efficacy of the SFIC block combined with LIA would be superior to that of an FN block combined with LIA in patients after THA.

This prospective, randomized, open-label study aimed to determine whether an SFIC block with LIA was superior to an FN block with LIA in postoperative THA analgesia.

2. MATERIALS AND METHODS

2.1 Patients

This single-center, open-label, randomized clinical trial was conducted in adherence with the

Declaration of Helsinki and approved by the Ethical Review Committee of Nagasaki Rosai Hospital (IRB No. 05002; May 29, 2023). This trial was registered with the University Hospital Medical Information Network (ID: UMIN 000052893). We studied 50 American Society of Anesthesiologists physical status 1 or 2 patients weighing 50–80 kg who underwent THA via the posterior approach under general anesthesia between May 2023 and March 2024. No age limit was set in the inclusion criteria for this study. The exclusion criteria were as follows: hepatic and renal dysfunction, local anesthetic allergy, weight < 50 or >80 kg. None of the patients received any pre-anesthetic medication.

2.2 Study Protocol

To achieve the desired effect-site concentration, the patients received a continuous infusion of remifentanyl 0.5 µg/kg/min and propofol 3 µg/mL via a target controlled infusion (TCI) system (TCI pump, Terumo, Tokyo, Japan). Rocuronium (0.8 mg/kg) was administered to facilitate tracheal intubation after loss of consciousness. The effect-site concentrations of propofol and remifentanyl were titrated to maintain a bispectral index score between 40 and 60 after tracheal intubation. Patients were randomly divided into two groups using the sealed envelope method: Group F (n=25), which received an ultrasound-guided FN block with 30 mL of 0.25% levobupivacaine and Group S (n= 25), which received an ultrasound-guided SFIC block with 30 mL of 0.25% levobupivacaine. Both nerve blocks were conducted in the supine position using high-frequency linear ultrasonography (ARIETTA 60, Hitachi Medical, Tokyo, Japan) by experienced anesthesiologists in charge prior to surgery. In the FN block, the ultrasound probe was placed in transverse orientation on the upper thigh just inferior to the inguinal ligament. After skin disinfection, a 23-gauge needle was inserted from outside to the inside, toward the FN, using the in-plane technique. In the SFIC block, the ultrasound probe was placed in a parasagittal orientation over the inguinal ligament, inferior medially to the anterior superior iliac spine. Using real-time ultrasound imaging, the internal oblique, sartorius, and iliacus muscles, covered by the fascia iliaca, were identified. The needle was inserted from the caudad-to-cephalad direction, via the sartorius muscle, directed toward the iliacus muscle. We noted that the local anesthetic spread under real-time imaging between the internal oblique and iliacus muscles.

Both groups received 20 mL of 0.25% levobupivacaine by the surgeon as LIA over the incision line into the muscle, and the subcutaneous and cutaneous tissue along the wound edge after fascia closure. All patients received bolus administration of 250 µg fentanyl before skin closure and 1000 mg intravenous acetaminophen prior to the end of the operation, and at 6, 12, 18, and 24 h after surgery. The patients received 50 mg of diclofenac sodium suppository, as rescue analgesics, as required. The nursing staff evaluated the postoperative pain via a numerical rating scale (NRS; 10 points from 0 to 10) at 0, 1, 3, 6, 12, 18, and 24 h at rest, postoperatively. Over 12 and 24 h postoperatively, the number of analgesics needed was recorded.

2.3 Measurement

The primary outcome was NRS at rest at 0, 1, 3, 6, 12, 18, and 24 h postoperatively, and the secondary outcome was the number of analgesic requirements over 12 and 24 h, postoperatively.

2.4 Statistical Analysis

The results are expressed as median (interquartile range). To analyze the interaction between time and the two groups, a two-way repeated-measures analysis of variance was conducted. A post hoc comparison between groups at each time point and among the repeated measures in each group was conducted using the Bonferroni procedure, if appropriate. Continuous data for patient characteristics were analyzed using the Mann–Whitney U test. Dichotomous variables were analyzed using the chi-squared test. Statistical significance was set at a *P*-value of < .05.

The sample size was determined according to a previous study (standard deviation, 2.44), which indicated that with 24 patients in each group, a power of 80% would be required to detect a difference of 2 in the NRS value between the two groups at a 5% significance level.

3. RESULTS

In our study, a total of 50 patients (15 men and 35 women) were included, and no patients were excluded.

Table 1 shows the patient characteristics for each group. The two groups showed no significant difference in patient characteristics, except for the intraoperative fluid balance.

Values are represented as median (interquartile range) or number. Group F, femoral nerve block group; Group S, suprainguinal fascia iliaca compartment block; n, number; BMI, body mass index

During the study period, the repeated-measures analysis of variance revealed no significant differences in the NRS scores between the two groups (*P* = .25) (Fig. 1).

The NRS scores at 24 h postoperatively were lower than those at 0, 1, and 3 h in Group F. The NRS score at 6 h postoperatively was lower than those at 1 and 3 h, and the NRS scores at 12 and 24 h postoperatively were lower than those at 0, 1, and 3 h in Group S.

Table 2 shows number of analgesic requirements postoperatively. No significant difference was found between the two groups in the number of analgesic requirements over 12 and 24 h, postoperatively.

Table 1. Patients variables and perioperative characteristics

	Group F	Group S	<i>P</i>
Patients (n)	25	25	
ASA PS 1/2 (n)	2/23	5/20	.42
Sex (male/female)	7/18	8/17	1.0
Age (years)	68 (62, 72)	67 (62, 73)	.87
Height (cm)	156 (151, 158)	153 (152, 160)	.83
Weight (kg)	64 (56, 68)	60 (57, 66)	.73
BMI (kg/m ²)	25.5 (23.8, 28.1)	25.7 (23.4, 27.2)	.95
Smoker (n)	7	8	1.0
Anesthetic time (min)	167 (163, 180)	163 (159, 176)	.30
Operative time (min)	87 (83, 100)	90 (84, 100)	.59
Intraoperative blood loss (ml)	200 (158, 273)	210 (165, 250)	.80
Intraoperative fluid balance (ml)	1020 (783, 1115)	680 (570, 980)	.01

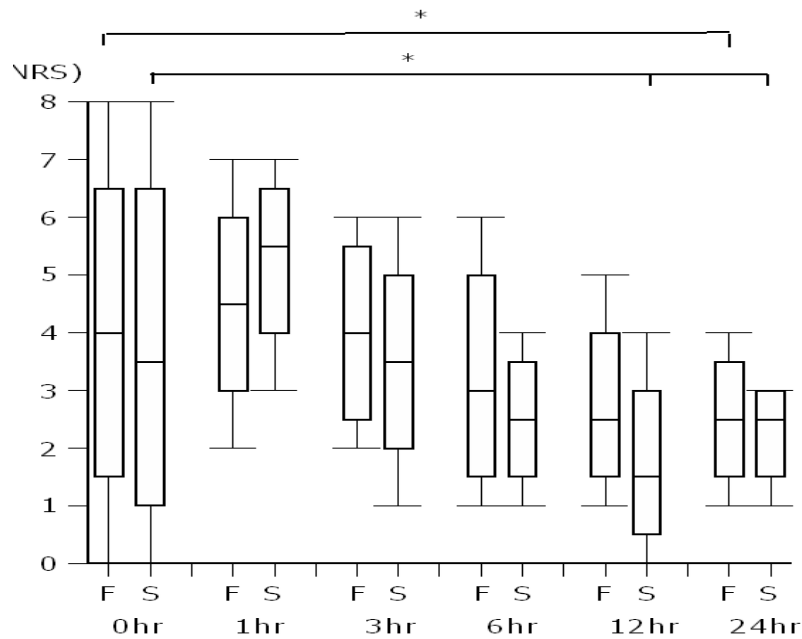


Fig. 1. Numerical rating scale in the group with a femoral nerve block (F) and suprainguinal fascia iliaca compartment block (S) at each time point. Values are expressed as median (line inside the boxes), interquartile range (boxes), and 10–90 percentiles (whiskers) F, femoral nerve block; S, suprainguinal fascia iliaca compartment block; NRS, numerical rating scale; *P < .05 vs. 0-h values

Table 2. Number of analgesic requirements postoperatively

	Group F	Group S	P
Rescue analgesics for 12 hr (n)	0 (0, 1)	0 (0, 1)	1.0
Rescue analgesics for 24 hr (n)	0 (0, 0)	0 (0, 0)	.15

Values are represented as median (interquartile range). Group F, femoral nerve block group; Group S, suprainguinal fascia iliaca compartment block; n, number.

4. DISCUSSION

Our study revealed no significant differences between the two groups in NRS scores and in the number of analgesic requirements during the first 24 h postoperatively. The study results indicate that the FN block with LIA and SFIC block with LIA may be equally effective in providing adjunctive analgesia after THA.

“Numerous trials exist comparing the analgesic efficacy of an FIC block and an FN block in hip fractures or after hip surgery. However, owing to the varying types and doses of local anesthetics utilized in numerous trials, the results of the comparison of the analgesic efficacy of an FIC block and an FN block in hip fractures or after hip surgery are inconclusive. An SFIC block is a

volume-dependent block requiring 30–40 mL of local anesthetic to spread sufficiently through the sub-fascial compartment” [7]. Considering that all our study participants in our study were Japanese and had a smaller body size than Westerners, the amount of levobupivacaine used for the SFIC block was set at 30 mL. Although some trials indicate that the FN block requires less local anesthetic and has a faster onset than the FIC block [8], our study utilized the same amount of local anesthetic in both groups to facilitate comparison.

Laumonerie et al. described that “the anterior capsule primarily supplied by the FN and ON and the superior labrum appear to be the primary pain generators in the hip joint” [10]. Referring to the results of Laumonerie’s study, it was suggested that the SFIC block, which has a higher probability of covering FN-, LFCN-, and ON-innervated areas, may provide a stronger analgesia than the FN block after THA. Contrary to our expectations, our study results revealed no

significant difference in terms of the analgesic efficacy between the FN block group and SFIC block group. Our results may be explained by the following reasons. First, the amount of local anesthetic utilized for the SFIC block may have been insufficient to spread the subfascial compartment and provide complete postoperative THA analgesia. The cadaveric dose-finding study explored the minimum effective volume of dye in 90% of cases (MEV90) for an ultrasound-guided SFIC block and concluded that the MEV90 of the dye required to stain the FN, LFCN, and ON was 62.5 mL [11]. Among the three nerves (FN, LFCN, and ON) targeted, the ON remains as the most challenging to anesthetize for the SFIC block. A study by Swenson et al. using magnetic resonance imaging demonstrated that performing an ultrasound-guided SFIC block with 30 mL of 0.25% bupivacaine revealed a reliable clinical effect on the FN and LFCN but showed no evidence of the ON [5]. However, caution should be exercised when using high doses of local anesthetics to achieve efficacy, as this may increase the risk of local anesthetic toxicity.

Second, the contribution of the analgesic effect of an ON block in postoperative THA may be small. Nielsen et al. described that opioid consumption after THA was not considerably reduced in the ON block compared with placebo [12]. Finally, considering that the SFIC block covers the LFCN-innervated area as well as the FN-innervated area, the SFIC block seems to have an advantage in terms of analgesia over the FN block; however, both blocks demonstrated the equivalent adjunctive analgesic effect after THA. The reason for this result may be attributed to the LIA over the incision line into the muscle in both groups, which may have provided equal coverage of the LFCN-innervated area to the same level.

For FN and SFIC blocks, the following points should be noted. FN and SFIC blocks can weaken the quadriceps muscles, which increases the associated risk of falls after THA [13]. However, in our study patients, no falls associated with nerve blocks occurred as they were transferred to a wheelchair on the first postoperative day and started walking in the rehabilitation room on the second day, accompanied by an occupational therapist.

Attention has recently been highlighted on the pericapsular nerve group (PENG) block, which provide analgesia comparable to or better than

the SFIC block while maintaining quadriceps muscle strength [14,15]. The musculofascial plane between the psoas tendon anteriorly and the pubic ramus posteriorly is the target area for the PENG block [15]. In the PENG block, the target area is deeper than the SFIC block and the target area it is often difficult to delineate by ultrasound, especially in obese patients. If ultrasound imaging is difficult, it may be easier and safer to perform the SFIC block than the PENG block.

The study limitations include the fact that it was a single-center study, it was not blinded, only the NRS at rest was evaluated, and there was potential for bias by the nursing staff who evaluated the NRS. Although all nerve blocks were conducted under ultrasound guidance, it may be possible that the local anesthetic was not distributed to the appropriate space and not efficacious. However, assuming that the nerve block failed and had little to no effect, we are convinced that a higher dose of opioids was required than was administered in our study protocol. In this study, there was a difference in the intraoperative fluid balance between the two groups in patient characteristics. On the other hand, there were no differences in operative time and intraoperative blood loss. The reason of the difference in intraoperative fluid balance is unknown. However, patients were randomly divided into two groups using the sealed envelope method. Moreover, no study has shown that intraoperative fluid balance differences affect postoperative pain, and these differences would have had little impact on the results of this study.

5. CONCLUSION

Both the FN block with LIA and the SFIC block with LIA would have the equivalent adjunctive analgesic effect after THA. However, further studies are warranted to conclude the comparative results of the analgesic effects of the SFIC and FN blocks.

DISCLAIMER (ARTIFICIAL INTELLIGENCE)

Author(s) hereby declare that NO generative AI technologies such as Large Language Models (ChatGPT, COPILOT, etc) and text-to-image generators have been used during writing or editing of manuscripts.

CONSENT AND ETHICAL APPROVAL

The study protocol was approved by the Institutional Research and Ethics Committee of

Nagasaki Rosai Hospital on May 29, 2023 (No. 05002). Written informed consent was obtained from all participants.

ACKNOWLEDGEMENTS

This research was supported by research funds to promote the hospital functions of the Japan Organization of Occupational Health and Safety. We thank ACN (www.t-acn.com) for the English language editing services.

COMPETING INTERESTS

Authors have declared that no competing interests exist.

REFERENCES

1. Terao Y, Oji M, Urabe S, Tominaga S, Fukusaki M, Hara T. Effect of lateral femoral cutaneous nerve block combined with femoral nerve block on postoperative pain after total hip arthroplasty: A retrospective study. *Eur J Anaesth* 2017; 34:e-suppl 55:86.
2. Shimasaki A, Terao Y, Komatsu Y. A Comparison of the Effect on Postoperative Pain between Lateral Femoral Cutaneous Nerve Block and Local Infiltration Anesthesia after Total Hip Arthroplasty: A Randomized Trial. *J Adv Med Med Res.* 2022;87-93. Accessed On: December 23. DOI:10.9734/jammr/2022/v34i244907
3. Jiménez-Almonte JH, Wyles CC, Wyles SP, et al. Is Local Infiltration Analgesia Superior to Peripheral Nerve Blockade for Pain Management After THA: A Network Meta-analysis. *Clin Orthop Relat Res.* 2016;474(2):495-516. DOI:10.1007/s11999-015-4619-9
4. Dolan J, Williams A, Murney E, Smith M, Kenny GNC. Ultrasound Guided Fascia Iliaca Block: A Comparison With the Loss of Resistance Technique. *Reg Anesth Pain Med.* 2008;33(6):526-531. DOI: 10.1016/j.rapm.2008.03.008
5. Swenson JD, Davis JJ, Stream JO, Crim JR, Burks RT, Greis PE. Local anesthetic injection deep to the fascia iliaca at the level of the inguinal ligament: The pattern of distribution and effects on the obturator nerve. *J Clin Anesth.* 2015;27(8):652-657. DOI: 10.1016/j.jclinane.2015.07.001
6. Vermeylen K, Desmet M, Leunen I. Supra-inguinal injection for fascia iliaca compartment block results in more consistent spread towards the lumbar plexus than an infra-inguinal injection: A volunteer study. *Reg Anesth Pain Med.* 2019;44(4):483-491. DOI:10.1136/rapm-2018-100092
7. Liang Y, Lv L, He L, Deng W, Chen C, Li J. A randomized controlled trial of FNB versus FICB for patients with femoral neck fractures before spinal anesthesia. *Clin Interv Aging.* 2020;15:1113-1119. DOI:10.2147/CIA.S251025
8. Li XD, Han C, Yu WL. Is Femoral nerve block superior to fascia iliac block in hip surgery? Meta-Analysis of randomized controlled trials. *Biomed Res Int.* 2022; 2022. DOI:10.1155/2022/4840501
9. Hebbard P, Ivanusic J, Sha S. Ultrasound-guided supra-inguinal fascia iliaca block: A cadaveric evaluation of a novel approach. *Anaesthesia.* 2011;66(4):300-305. DOI:10.1111/j.1365-2044.2011.06628.x
10. Laumonerie P, Dalmas Y, Tibbo ME. Sensory innervation of the hip joint and referred pain: A systematic review of the literature. *pain medicine (United States).* 2021;22(5):1149-1157. DOI: 10.1093/pm/pnab061
11. Kantakam P, Maikong N, Sinthubua A, Mahakkanukrauh P, Tran DQ, Leurcharusmee P. Cadaveric investigation of the minimum effective volume for ultrasound-guided suprainguinal fascia iliaca block. *Reg Anesth Pain Med.* 2021;46(9):757-762. DOI:10.1136/rapm-2021-102563
12. Nielsen ND, Runge C, Clemmesen L. An obturator nerve block does not alleviate postoperative pain after total hip arthroplasty: A Randomized Clinical Trial. *Reg Anesth Pain Med.* 2019;44(4): 466-471. DOI:10.1136/rapm-2018-100104
13. Wang QR, Ma T, Hu J, Yang J, Kang PD. Comparison between ultrasound-guided pericapsular nerve group block and anterior quadratus lumborum block for total hip arthroplasty: a double-blind, randomized controlled trial. *Eur Rev Med Pharmacol Sci.* 2023;27:7523-7532.
14. Kong M, Tang Y, Tong F. The analgesic efficacy of pericapsular nerve group block in patients with intertrochanteric femur

- fracture: A randomized controlled trial. PLoS One. 2022;17.
DOI: 10.1371/journal.pone.0275793
15. Gonabal V, Aggarwal S, Rani D, Panwar M. Comparison of ultrasound-guided suprainguinal fascia iliaca compartment block and pericapsular nerve group block for postoperative analgesia and associated cognitive dysfunction following hip and proximal femur surgery. J Anaesthesiol Clin Pharmacol. Accessed On:December 12, 2023.
DOI: 10.4103/joacp.joacp_230_23

Disclaimer/Publisher's Note: The statements, opinions and data contained in all publications are solely those of the individual author(s) and contributor(s) and not of the publisher and/or the editor(s). This publisher and/or the editor(s) disclaim responsibility for any injury to people or property resulting from any ideas, methods, instructions or products referred to in the content.

© Copyright (2024): Author(s). The licensee is the journal publisher. This is an Open Access article distributed under the terms of the Creative Commons Attribution License (<http://creativecommons.org/licenses/by/4.0>), which permits unrestricted use, distribution, and reproduction in any medium, provided the original work is properly cited.

Peer-review history:
The peer review history for this paper can be accessed here:
<https://www.sdiarticle5.com/review-history/120289>