



## Visceral Artery Aneurysms: A Complex and Unresolved Issue

**Bahaa Arefai<sup>1</sup>, Mariam Perea-Ribis<sup>2</sup>, Benet Gómez<sup>1</sup>, Natalia Rodríguez<sup>1</sup>,  
Patricia Hernández<sup>3</sup>, Jordi Camps<sup>2</sup>, Jorge Joven<sup>2</sup>, Anna Hernández-Aguilera<sup>2\*</sup>  
and Vicente Martín-Paredero<sup>1</sup>**

<sup>1</sup> Servei d'Angiologia, Cirurgia Vasculard i Endovascular, Hospital Universitari Joan XXIII, Tarragona, Spain.

<sup>2</sup> Unitat de Recerca Biomèdica, Universitat Rovira i Virgili, Reus, Tarragona, Spain.

<sup>3</sup> Servei de Radiologia i Medicina Nuclear, Hospital Universitari Joan XXIII, Tarragona, Spain.

### Authors' contributions

*This work was carried out in collaboration between all authors. Authors VMP, BG, NR and BA contributed to diagnosis and surgical management of the patient. Authors JJ, MPR, JC and AHA have contributed substantially to the conception, design, analysis and interpretation of data and have been involved in drafting of the manuscript and pictures. Authors VMP and BA critically revised the intellectual content. Author PH has contributed to acquisition of data. All authors read and approved the final manuscript.*

### Article Information

DOI: 10.9734/IJMPCR/2015/19030

#### Editor(s):

(1) Jignesh G. Patel, Department of Pathology, University of Texas Medical Branch at Galveston, Texas, USA.

#### Reviewers:

(1) Aşkın Ender Topal, Cardiovascular Surgery, Dicle University, Turkey.

(2) Andrea Borghini, Institute of Clinical Physiology, CNR, Italy.

(3) Anonymous, Bulgaria.

(4) Anonymous, Russia.

Complete Peer review History: <http://sciencedomain.org/review-history/10106>

**Case Study**

**Received 22<sup>nd</sup> May 2015**  
**Accepted 20<sup>th</sup> June 2015**  
**Published 8<sup>th</sup> July 2015**

### ABSTRACT

**Aims:** The lack of prospective studies on abdominal non-aortic true or false aneurysms results in insufficient data to predict their natural history and propose a treatment of choice. The experience provided by case reports is important to discuss their management and prevention. This is relevant because abnormal enlargements in superior mesenteric artery are relatively uncommon but associated with specific symptoms and a high incidence of rupture and/or ischemic bowel complications.

\*Corresponding author: E-mail: [anna.hernandeza@gmail.com](mailto:anna.hernandeza@gmail.com);

**Presentation of Case:** Open surgery was preferred in a giant true aneurysm with an associated arteriovenous fistula, due to the likely need for revascularization and probable lack of stability for a stent graft. Contrarily in a pseudoaneurysm with a similar size we performed coil embolization. Incidentally, this procedure required a subsequent deployment of a covered stent graft to resolve bleeding.

**Discussion:** We discuss the outcomes of true and false aneurysms in the superior mesenteric artery, which required urgent treatment due to their high diameter. Their extremely large size also suggests a protracted course and a considerable period of time without proper surveillance through imaging techniques. Endovascular techniques seem to be favored in the elective setting and open surgery in the emergent setting but the challenge for the vascular surgeon to choose a treatment is considerable. Patient's clinical state, perceived risk of rupture, the size of the lesion and expected quality of life conditioned the choice.

**Conclusion:** The described cases illustrate the urgent requirement of treatment guidelines and/or screening programs to detect abdominal non-aortic aneurysms at an early stage.

*Keywords: Visceral artery aneurysms; pseudoaneurysms; risk assessment; screening; superior mesenteric artery.*

## ABBREVIATIONS

AAA : Abdominal aortic aneurysm  
CT : Computed tomography  
ICU : Intensive care unit  
SMA : Superior mesenteric artery  
VAA : Visceral artery aneurysms  
VAPA: Pseudoaneurysms

## 1. INTRODUCTION

Aneurysms involving splenic, gastro-duodenal, hepatic, superior mesenteric and renal arteries are commonly referred as visceral artery aneurysms (VAAs). Pseudoaneurysms (VAPAs) are contained ruptures in the respective vessel wall with collection of blood. Both may result in massive hemorrhage. Their actual prevalence is difficult to calculate because the use of rapid and relatively simple imaging techniques is associated with an apparently growing incidence.

It is generally accepted that true aneurysms may be unrelated to the presenting complaint, whereas pseudoaneurysms are most likely symptomatic. This assumption is apparently inaccurate in superior mesenteric artery (SMA) enlargements, which are commonly associated with abdominal pain and a high operative mortality rate. Case reports are the only sources of available data to characterize this condition and, consequently, there are no clinical guidelines [1-5]. However, current clinical experience increasingly suggests that endovascular repair in most cases represent a promising alternative to the more classical open-surgery procedures. Here we describe two

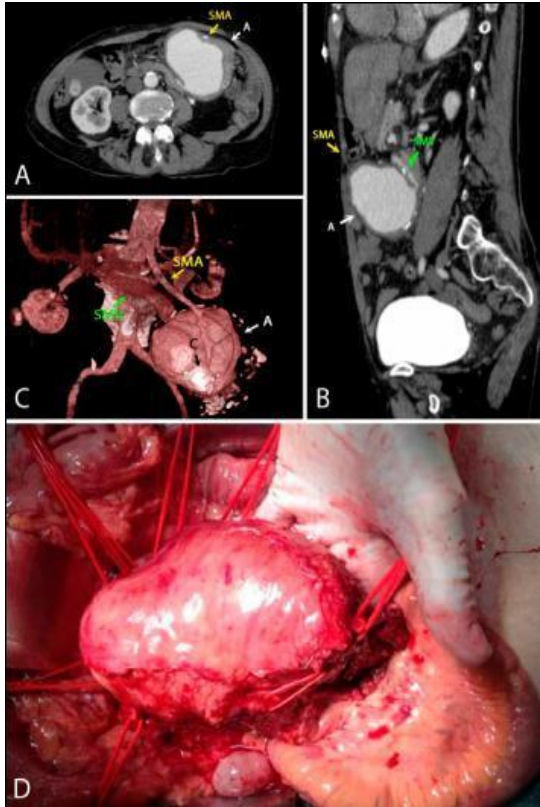
observations illustrating the challenge that represent the different diagnostic procedures, assessment of risk and therapeutic alternatives. Conservative options (i.e., watchful waiting) were not considered due to the size and risk of rupture and the Surgical Review Board of the Hospital Joan XXIII has previously approved the possible interventional procedures. Informed consents were obtained according to guidelines provided by the Ethics Committee (OBESPAD 14-07-31/7proj3).

## 2. PRESENTATION OF CASES

### 2.1 Case 1

A 68 year-old, non-smoker female was admitted to our Hospital presenting an 8-hour history of intense and oppressive thoracic and abdominal pain, which radiated to the neck and was accompanied by diaphoresis and vomiting. Myocardial infarction was discarded and a large, firm and pulsatile mass was palpable in the abdomen with a clear murmur under auscultation. She had a past medical history of rheumatic fever, which required the implant of a mechanical prosthetic mitral valve and left hemiplegia resulting from a previous stroke during an episode of postpartum infective endocarditis. A computed tomography (CT) scan showed an 11-cm (in diameter) true aneurysm at the distal segment of SMA, the concomitant presence of peripheral calcification and an arteriovenous fistula causing enlargement of the mesenteric vein (Figs. 1A-C). A medial laparotomy was performed and the adhesions to the adjacent tissue were removed to control the

proximal and distal aneurysm necks. Other vessels present in the anatomical area of influence of the aneurysm were provisionally clamped (more than 30 min) without apparent signs of ischemia (Fig. 1D).



**Fig. 1. Management of visceral artery aneurysms**

*Non-invasive imaging techniques, in particular computed tomography angiogram scans were important for the diagnosis of a giant true aneurysm (A) arising from the distal branches of the superior mesenteric artery (SMA) and an arteriovenous fistula causing an enlargement of the superior mesenteric vein (SMV) (A,B). Other anatomical details were provided by a three-dimensional reconstruction, including the present of calcification (C). Clamping of the aneurysmal sac for more than 30 min apparently excluded the presence of ischemic bowel (D), a procedure that should be re-assessed according to the unsatisfactory outcome*

Thus, the aneurysmal sac was opened, the retrograde bleeding from the fistula contained, and full resection of aneurysmal sac was performed without grafting. The abdomen incision was then maintained open under a negative pressure abdominal closure dressing and the patient was carefully monitored at the Intensive Care Unit (ICU). Approximately 24

hours after this surgical procedure there was an acute severe ischemic event affecting portions of jejunum and ileum that required surgical intervention. The patient died 24 hours after this further intervention due to related complications. The search in blood and tissues for infective agents was negative and the histology in portions of the excised artery depicted advanced atherosclerosis.

## 2.2 Case 2

A 58-year-old female with a history of smoking and high alcohol intake was admitted to our Hospital presenting a 6-hour intense and diffuse abdominal pain, nausea and vomiting. Clinical records depicted a past medical history of chronic pancreatitis, liver cirrhosis, portal hypertension, and non-bleeding esophageal varices. A palpable, painful and pulsatile mass was found in epigastrium. Laboratory studies and subsequent arteriography and CT scans suggested the provisional diagnosis of an arterial pseudoaneurysm, which was complicating active pancreatitis. We found a 10-cm (in diameter) blood collection with signs of a recent bleeding involving SMA (Figs. 2A, B). In this case, the decision was to perform endovascular treatment. The brachial artery was punctured and the SMA was catheterized to reach the pseudoaneurysm neck with a Progreat™ microcatheter (Terumo, Tokyo, Japan). We first released hilar embolization microcoils™ (Cook Medical, Bloomington, IN, USA) at the bleeding point but control CT scans depicted a leak providing a persistent inflow filling of the pseudoaneurysmatic sac through the microcoils (Figs. 2C, D). Then, a covered stent graft (Bentley InnoMed, Hechingen, Germany) was positioned. The complete resolution of the endoleak and the patency of the stent graft were verified through angiography (Fig. 3). After 3 days of follow-up at the ICU, the patient was referred to their attending physicians at the Gastroenterology Department without further related vascular complications.

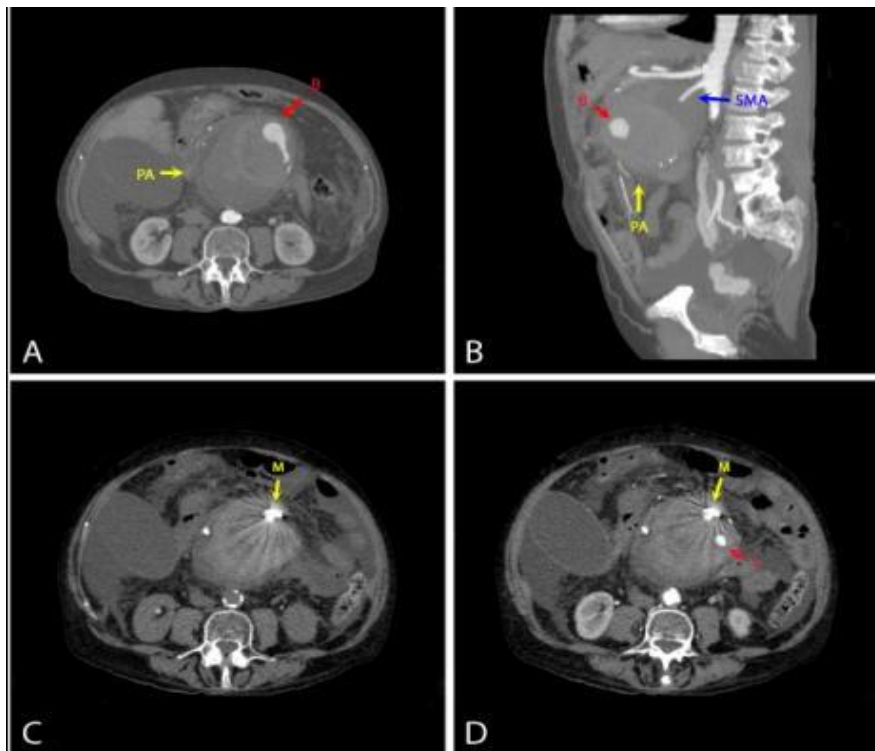
## 3. DISCUSSION

Patients with VAAs have intact arterial layers but in VAPAs the arterial wall is incomplete. The described cases illustrate the need to collect epidemiological data on the prevalence, incidence and mortality rate of abdominal non-aortic true or false aneurysms (i.e., abnormally enlarged visceral arteries). The reported

prevalence is not different from that estimated for abdominal aortic aneurysms (AAA) (approximately 2%) and their threatening complications are potentially avoidable [6]. The frequency of occurrence of VAAs and VAPAs is apparently increasing as a result of incidental discoveries during imaging examinations and many true aneurysms and essentially all pseudoaneurysms require treatment [7,8]. The size of lesions in our two case reports in combination with the perceived risk for the patient indicated urgent treatment because complications were likely and life threatening (e.g., thrombosis and/or embolization, compression of adjacent structures and hemorrhage from rupture). Aneurysms in SMA represent a 5-7% of VAAs but mortality is apparently higher than that observed in other arteries, especially when the treatment is not elective [9]. Trauma, infection and even degenerative processes have been formerly described among the causes of aneurysms but atherosclerosis is now recognized as the primary event in the pathogenesis of these disorders

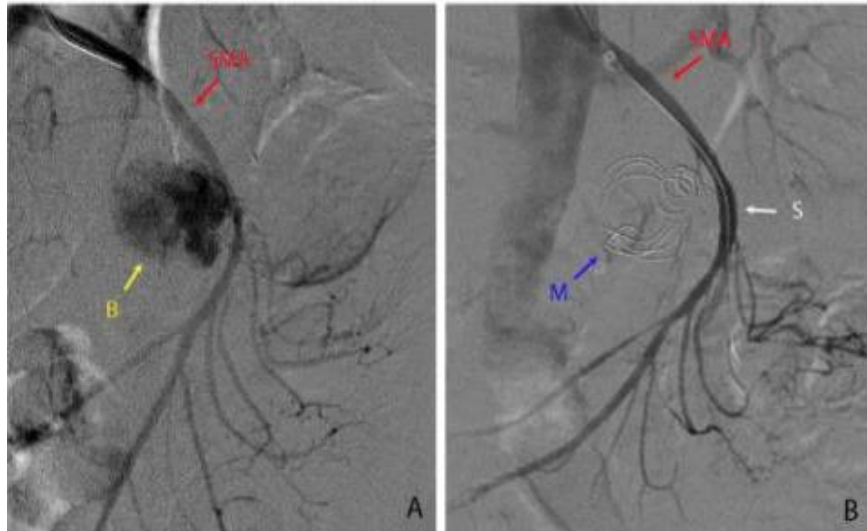
[4,5,9]. Consequently, it is important to reinforce the strategy of risk-factor modification, which might reduce the rate of aneurysmal growth (i.e., cessation of smoking, treatment of hypertension and/or of hypercholesterolemia, or drugs that inhibit the renin-angiotensin pathway and/or the expression of metalloproteinases) [10].

Unlike other VAAs, SMA aneurysms (true and false) are symptomatic. However, laboratory data, symptoms and signs are not sufficient to discriminate between true and false aneurysms and require the use of imaging techniques. There are no gender differences in distribution but the incidence of ischemic bowel and rupture is apparently high [8,11]. Clinical manifestations include abdominal pain and a palpable and pulsatile abdominal mass [6]. This fact is clearly illustrated in the current cases report and it suggests the importance of contrast material-enhanced abdominal CT examination for rapid diagnosis. Magnetic resonance imaging represents a valid alternative because the new techniques provide additional vascular



**Fig. 2. A giant pseudoaneurysm illustrates the value of endovascular treatment in hostile environment for abdominal surgery**

*Contrast-enhanced computed tomography scans before endovascular treatment (A, B) depicted a superior mesenteric pseudoaneurysm (PA) with signs of active bleeding (B). Further imaging studies after endovascular management confirmed that microcoils were into the aneurysm sac (C) but also the persistence of a leak (L) indicating an unresolved blood inflow (D), which required a stent graft*



**Fig. 3. Arteriography remains a valuable tool in surgical management**

*Findings in Fig. 2 (C, D), including active bleeding (B) were further confirmed by angiography demonstrating the value of this technique for further diagnosis (A). The procedure also detected the presence of microcoils (M) and guided the deployment of the covered stent in the mesenteric superior artery (SMA), which resolved this clinical condition (B)*

information. Ultrasonography was useless in the management of these patients but angiography remained as an important tool for treatment and further diagnosis.

The choice of treatment is a challenging task. The clinical condition of the two patients in the current study was not comparable but size and shape was determinant to guide decisions. In both cases the Laplace's law (i.e., Tension = Pressure x Radius) suggests a high rate of expansion and even the adoption of a spherical shape could not limit the expansion due to the increased wall tension. Some authors consider open-surgery a better choice for VAAs and VAPAs of this size, but the current experience in endovascular treatment is apparently contradictory to this assumption and a matter of discussion [12-17]. Similar clinical situations will require a prompt response and decision from the vascular surgeon. Open-surgery may provide definitive treatment (i.e., higher durability and reduced need for follow-up studies), which includes the possibility for a better evaluation of the need for revascularization of the affected organs. This is especially important in arteries such as SMA with inadequate flow or others without collateral flow. On the other hand, catheter-based interventions may be difficult to perform in the emergency setting and anatomy, size and predicted complications should be carefully considered. Hence, the goal should be

to develop ways for exclusion of the aneurysm's sac from the circulation and to preserve distal flow. Although most deaths occur in patients undergoing urgent repair [1,5,15,18], elective treatments (after surveillance and/or medical treatment) were considered unrealistic in these cases.

In case 1, we chose open surgery due to the perceived high risk of rupture, the likely need for revascularization and a probable lack of stability for a stent graft [4]. We also predicted the likelihood of multiple vessels originating from the proximal and distal necks of the aneurysm and that endovascular treatment will probably result in a conversion to an open surgery procedure (i.e., over-imposed complications). Because clamping for more than 30 minutes did not depict intestinal ischemic changes, the procedure was considered successful but this decision requires further evaluation because ischemic events and subsequent intestinal resection are not uncommon. In case 2, however, the performed laboratory studies suggested the presence of acute pancreatitis (namely increased serum levels of amylase and lipase). These results combined with those provided by imaging techniques clearly suggested the presence of an hostile environment for abdominal surgery and we decided to perform coil embolization as a minimally invasive endovascular technique, which provides a decreased length of hospital

stay, and better quality of life. Of note, a leak was further resolved by the deployment of a covered stent graft [19,20]. This procedure occluded two arterial branches but without clinical signs of ischemia and a satisfactory follow-up. Knowledge and tools designed to improve endovascular treatment are in constant expansion. Although some complications have been reported, current alternatives include the use of flow-diverting stents or multilayer fluid modulating stents designed to reduce the flow velocity allowing for physiological thrombosis [13,17]. Our experience suggests that open surgery should be the first choice for unstable patients with established rupture or in high clinical risk but endovascular repair, once limited to elective options and stable patients, deserves further consideration in more patients.

#### 4. CONCLUSION

The frequency of occurrence of VAAs/ VAPAs is considerable. SMA aneurysms are relatively uncommon but frequently symptomatic and represent a dangerous type of VAA because of the high incidence of ischemic bowel complications. All SMA pseudoaneurysms are symptomatic and should be suspected in the presence of concurrent inflammatory diseases (especially pancreatitis). There are no prospective studies to properly define their prevalence and natural history. Therefore, the indication of treatment remains individualized and likely determined by the size and the perceived risk of rupture. Current approach for VAAs/ VAPAs is early intervention and endovascular techniques seem to be favored. These are especially considered in the elective setting but open surgery is likely the preferred method in giant aneurysms in the emergent setting. Our data illustrate that perhaps it is time to seriously consider screening policies to detect minor lesions and an active approach to follow-up their likely expansion.

#### CONSENT

Written informed consent was obtained from one patient and the next of kin from other for publication of details of these case reports, including images, ensuring anonymity for the eventual readers.

#### COMPETING INTERESTS

Authors have declared that no competing interests exist.

#### REFERENCES

1. Sachdev U, Baril DT, Ellozy SH, Lookstein RA, Silverberg D, Jacobs TS, et al. Management of aneurysms involving branches of the celiac and superior mesenteric arteries: A comparison of surgical and endovascular therapy. *J Vasc Surg.* 2006;44(4):718-24.
2. Stone WM, Abbas M, Cherry KJ, Fowl RJ, Gloviczki P. Superior mesenteric artery aneurysms: Is presence an indication for intervention? *J Vasc Surg.* 2002;36(2): 234-7.
3. Pulli R, Dorigo W, Troisi N, Pratesi G, Innocenti AA, Pratesi G. Surgical treatment of visceral artery aneurysms: A 25-year experience. *J Vasc Surg.* 2008;48(2): 334-42. DOI: 10.1016/j.jvs.2008.03.043
4. Jiang J, Ding X, Su Q, Zhang G, Wang Q, Jian W, et al. Therapeutic management of superior mesenteric artery aneurysms. *J Vasc Surg.* 2011;53(6):1619-24. DOI: 10.1016/j.jvs.2011.02.004
5. Frankhauser GT, Stone WM, Naidu SG, Oderich GS, Ricotta JJ, Money SR, et al. The minimally invasive management of visceral artery aneurysms and pseudoaneurysms. *J Vasc Surg.* 2011; 53(4):966-70. DOI: 10.1016/j.jvs.2010.10.071
6. Svensjö S, Björck M, Gürtelschmid M, Djavani Gidlund K, Hellberg A, Wanhainen A. Low prevalence of abdominal aortic aneurysm among 65-year-old Swedish men indicates a change in the epidemiology of the disease. *Circulation.* 2011;124(10):1118-23. DOI:10.1161/CIRCULATIONAHA.111.030379
7. Noshier JL, Chung J, Brevetti LS, Graham AM, Siegel RL. Visceral and renal artery aneurysms: A pictorial essay on endovascular therapy. *Radiographics.* 2006;26(6):1687-704.
8. Messina LM, Shanley CJ. Visceral artery aneurysms. *Surg Clin North Am.* 1997; 77(2):425-42.
9. Chadha M, Ahuja C. Visceral artery aneurysms: Diagnosis and percutaneous management. *Semin Intervent Radiol.* 2009;26(3):196-206. DOI: 10.1055/s-0029-1225670
10. Meijer CA, Stijnen T, Wasser MN, Hamming JF, Van Bockel JH, Lindeman JH. Doxycycline for stabilization of

- abdominal aortic aneurysms: A randomized trial. *Ann Intern Med.* 2013; 159(12):815-23.
11. Lorelli DR, Cambria RA, Seabrook GR, Towne JB. Diagnosis and management of aneurysms involving the superior mesenteric artery and its branches--a report of four cases. *Vasc Endovascular Surg.* 2003;37(1):59-66.
  12. Cochenec F, Riga CV, Allaire E, Cheshire NJ, Hamady M, Jenkins MP, et al. Contemporary management of splachnic and renal artery aneurysms: Results of endovascular compared with open surgery from two European vascular centers. *Eur J Vasc Endovasc Surg.* 2011;42(3):340-6.  
DOI: 10.1016/j.ejvs.2011.04.033
  13. Sholomovitz E, Jaskolka JD, Tan KT. Use a flow-diverting uncovered stent for the treatment of a superior mesenteric artery aneurysm. *J Vasc Interv Radiol.* 2011; 22(7):1052-55.  
DOI: 10.1016/j.jvir.2011.02.006
  14. Marone EM, Mascia D, Kahlberg A, Brioschi C, Tshomba Y, Chiesa R. Is open repair still the gold standard in visceral artery aneurysm management? *Ann Vasc Surg.* 2011;25(7):936-46.  
DOI: 10.1016/j.avsg.2011.03.006
  15. Tulsyan N, Kashyap VS, Greenberg RK, Sarac TP, Clair DG, Pierce G, et al. The endovascular management of visceral artery aneurysms and pseudoaneurysms. *J Vasc Surg.* 2007;45(2):276-83.
  16. Keda O, Tamura Y, Nakasone Y, Iryon Y, Yamashita Y. Non operative management of unruptured visceral artery aneurysms: Treatment by transcatheter coil embolization. *J Vasc Surg.* 2008;47(6): 1212-9.  
DOI: 10.1016/j.jvs.2008.01.032
  17. Ferrero E, Viazzo A, Ferri M, Robaldo A, Piazza S, Berardi G, et al. Management and urgent repair of ruptured visceral artery aneurysms. *Annals of Vasc Surg.* 2011;25(7):e7-11.  
DOI: 10.1016/j.avsg.2011.02.041
  18. Cordova AC, Sumpio BE. Visceral artery Aneurysms and pseudoaneurysms-should they all be managed by endovascular techniques? *Ann Vasc Dis.* 2013;6(4): 687-93.
  19. Gabelmann A, Görich J, Merkle EM. Endovascular treatment of visceral artery aneurysms. *J Endovasc Ther.* 2002;9(1): 38-47.
  20. Uberoi R, Chung D. Endovascular solutions for the management of visceral aneurysms. *J Cardiovasc Surg (Torino).* 2011;52(3):323-31.

© 2015 Arefai et al.; This is an Open Access article distributed under the terms of the Creative Commons Attribution License (<http://creativecommons.org/licenses/by/4.0>), which permits unrestricted use, distribution, and reproduction in any medium, provided the original work is properly cited.

*Peer-review history:*  
*The peer review history for this paper can be accessed here:*  
<http://sciedomain.org/review-history/10106>