



# Fungal and Parasitic Diseases Seen in Tissue Biopsies at a Tertiary Health Center in Southwest Nigeria in a Five-Year Period

Olaejirinde Olaniyi Olaofe <sup>a\*</sup>, Ademola Idowu Soremekun <sup>a</sup>,  
Bolatito Opeyemi Olopade <sup>b</sup> and James Oluwatomi Oladele <sup>a</sup>

<sup>a</sup> Department of Morbid Anatomy and Forensic Medicine, Faculty of Basic Medical Sciences, College of Health Sciences, Obafemi Awolowo University, Ile-Ife, Osun State, Nigeria.

<sup>b</sup> Department of Medical Microbiology and Parasitology, Faculty of Basic Medical Sciences, College of Health Sciences, Obafemi Awolowo University, Ile-Ife, Osun State, Nigeria.

## Authors' contributions

This work was carried out in collaboration among all authors. All authors read and approved the final manuscript.

## Article Information

DOI: 10.9734/IJTDH/2023/v44i111438

## Open Peer Review History:

This journal follows the Advanced Open Peer Review policy. Identity of the Reviewers, Editor(s) and additional Reviewers, peer review comments, different versions of the manuscript, comments of the editors, etc are available here: <https://www.sdiarticle5.com/review-history/101323>

Original Research Article

Received: 12/04/2023

Accepted: 16/06/2023

Published: 23/06/2023

## ABSTRACT

**Aim:** To describe the clinical and pathological features of the various fungal and parasitic diseases seen at our hospital over a five-year period.

**Study Design:** This is a retrospective study of records of fungal and parasitic diseases.

**Place and Duration of Study:** The study was done at the Department of Morbid Anatomy and Forensic Medicine of Obafemi Awolowo University Teaching Hospitals Complex, Ile-Ife from January 2018 to December 2022.

\*Corresponding author: Email: oolaofe@oauife.edu.ng;

**Methods:** The tissue sections of each case went through routine processing in the histopathology laboratory. The slides of the sections were viewed using a simple binocular microscope. The slides were scanned using APERIO CS2 digital slide scanner.

**Results:** Eight cases of fungal infections and eleven cases of parasitic infections were noted during the study period. Aspergillosis accounted for five of the fungal infections, while mucormycosis accounted for two nasal infections. Schistosomiasis accounted for six cases of parasitic infections.

**Conclusion:** Aspergillosis was the most diagnosed fungal infection while Schistosomiasis was the commonest parasitic infection. Digital stain separation could be an added tool in identification of fungal and parasitic stages in histological tissue sections.

*Keywords: Mycoses; parasitic diseases; biopsy; schistosomiasis; cysticercosis; histoplasmosis.*

## 1. INTRODUCTION

Fungal and parasitic diseases are still serious health challenges in many countries around the world. These diseases are a major cause of morbidity and mortality in many countries in the tropical regions of the world [1]. Superficial infections, particularly of the epidermis of the skin by fungal organisms are usually not life threatening. However, a major concern is fungal infection that involves subcutaneous tissues or other deep tissues and organs of the body [2]. Parasites, which are commonly found in the intestinal lumen are associated with significant morbidity particularly when there is heavy intensity of infection. Parasites involving tissues and organs can result in significant morbidity and can be fatal in some cases.

Fungal infections that have been identified in Africa include histoplasmosis, chromoblastomycosis, aspergillosis, cryptococcosis, blastomycosis, coccidioidomycosis, mucormycosis, and sporotrichosis [3]. Aspergillosis is a common fungal infection world-wide because of the ubiquitous nature of the organism. It has been reported in many tissues of the body. It can coexist with other fungal infections which can be a high risk of fatality [4,5]. Aspergillosis and other deep mycotic infections have the potential of leading to devastating consequences if not detected early. Many of these infections are in a background of underlying illnesses such as immunodeficiency syndromes and diabetes mellitus [6,7]. Many laboratories in Nigeria are not adequately equipped to easily detect fungal infections, hence, some of them are at an advanced stage of tissue invasion when eventually diagnosed [8].

Diagnosis of fungal infections, especially of deep-seated tissues and organs are easily

missed. They are commonly diagnosed as other clinical entities before identification in tissue biopsies [3,9,10]. A high index of suspicion by clinicians in Africa is necessary for early detection of fungal diseases.

Schistosomiasis and cysticercosis are some of the main parasites that have been reported in various tissues in patients from many areas of the world. They are found in tropical countries where they cause significant morbidity. However, many cases have been reported in immigrants to other parts of the world where they are not endemic [11,12]. Schistosomiasis, a neglected tropical parasitic disease, is one of the most common parasites that has been reported mainly in the urinary and gastrointestinal systems [13–15]. Cysticercosis can affect many tissues of the body and can be particularly debilitating if the brain or spinal cord is involved [16]. Neurocysticercosis is known to be the cause of a large proportion of adult-onset seizures.

The aim of our study was to describe the clinical and pathological features of the various fungal and parasitic diseases seen at our hospital over a five-year period.

## 2. MATERIALS AND METHODS

We conducted a retrospective study of all cases of fungal and parasitic diseases diagnosed in tissue biopsies at the Department of Morbid Anatomy and Forensic Medicine of Obafemi Awolowo University Teaching Hospitals Complex, Ile-Ife from January 2018 to December 2022. Information on the biodata and mode of presentation was obtained from the medical records. Only cases where at least one stage of the organism was identified at tissue biopsy was included in the study. Cases with insufficient data or missing tissue blocks were excluded from the study. The tissue sections for the cases went

through routine processing in histopathology lab and were stained with hematoxylin and eosin. Where necessary, special histochemical stains like periodic acid Schiff and Gomori-methenamine silver were used to show the organism. The tissue sections of each case went through routine processing in histopathology laboratory. The sections were viewed using a simple binocular microscope. The slides were then scanned using APERIO CS2 digital slide scanner to produce scanscope virtual slide [SVS] format and then viewed in Qu Path 0.4.3 software on a computer workstation. The cases were then studied and compared with reports in the literature.

### 3. RESULTS

Eight cases of fungal infections and eleven cases of parasitic infections were noted during the study period. The fungal infections accounted for 42.1% and the parasitic infections accounted for 57.9%. We did not exclude any case from the study. Aspergillosis accounted for five of the fungal infections, while mucormycosis accounted for two nasal infections. A case of histoplasmosis of the bone was seen during the study period. The details of the fungal infections are presented in Table 1. All the cases of fungal infections were seen in trucut and incisional biopsies except the

two pulmonary cases that were identified in resections (lobectomy). The parasitic infections seen in resected specimens were in the two soft tissue masses, two ureteric segments, and the appendix. Other parasitic infections were seen in trucut or incisional biopsies.

Schistosomiasis accounted for six cases (54.5%) of parasitic infestation while cysticercosis accounted for four cases (36.3%). The details of the cases of parasitic infestations are presented in Table 2.

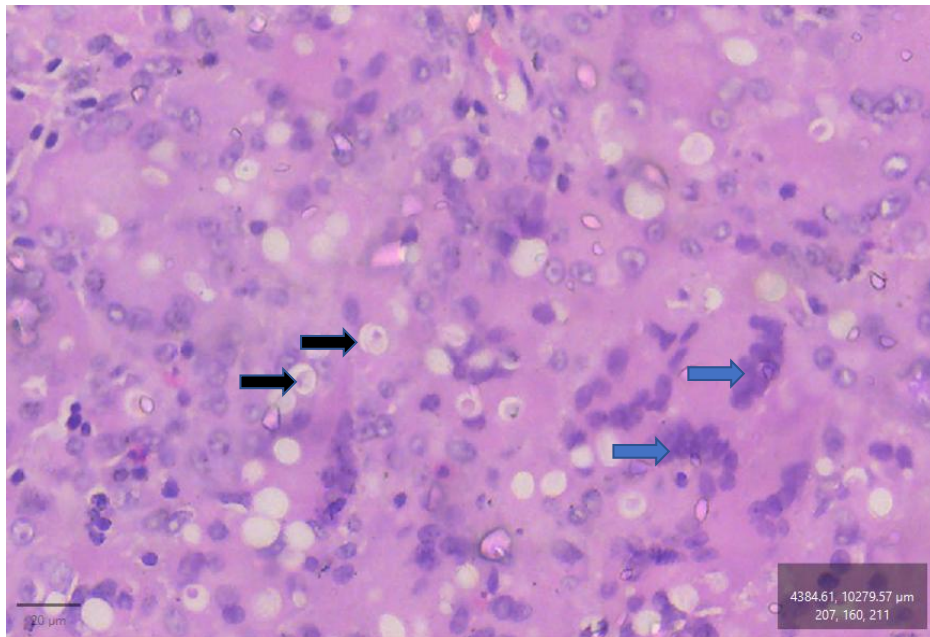
We observed that use of residual colour deconvolution for stain separation showed differences between some structures of fungal and parasitic bodies and the surrounding tissues. In a residual colour deconvolution of a digitally scanned haematoxylin and eosin-stained section of histoplasmosis of the bone viewed using Qu Path software, the spherical structures that were whitish in haematoxylin and eosin-stained section appear dark while the nuclei of the multinucleated giant cells that were dark appear whitish. This is shown in Figs. 1 and 2. In a residual colour deconvolution of a digitally scanned haematoxylin and eosin-stained section of cysticercosis of the brain viewed using Qu Path software, the sectioned hooklets appear dark.

**Table 1. Fungal infections in tissue biopsies**

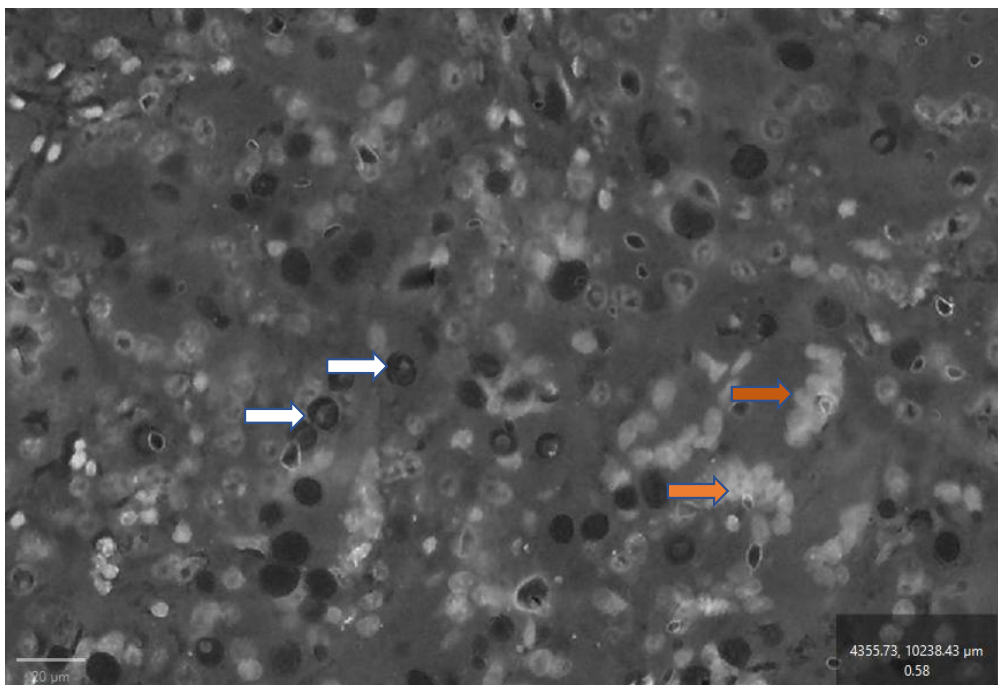
S. No	Age (years)	Sex	History	Organ/Tissue	Diagnosis
1	44	M	Six-month history of right sided nasal obstruction and loss of vision. Had diabetes mellitus.	Nasal	Mucormycosis
2	42	M	Had pulmonary tuberculosis eleven years prior to presentation. Had cough and hemoptysis	Lung	Aspergillosis
3	52	F	Nasal blockage and discharge	Nasal antral tissue	Mucormycosis
4	45	M	Hematuria with passage of fleshy material par urethra.	Bladder	Aspergillosis
5	33	F	Bilateral breast masses with clinical suspicion of inflammatory carcinoma	Breast	Aspergillosis
6	55	M	Recurrent cough, hemoptysis, and weight loss of four months duration.	Lung	Aspergillosis
7	49	F	Twelve-year history of recurrent nasal discharge	Nasal	Aspergillosis
8	36	M	Right shoulder pain for one year. Reduced range of movement of the shoulder	Bone	Histoplasmosis

**Table 2. Parasitic infection in tissue biopsies**

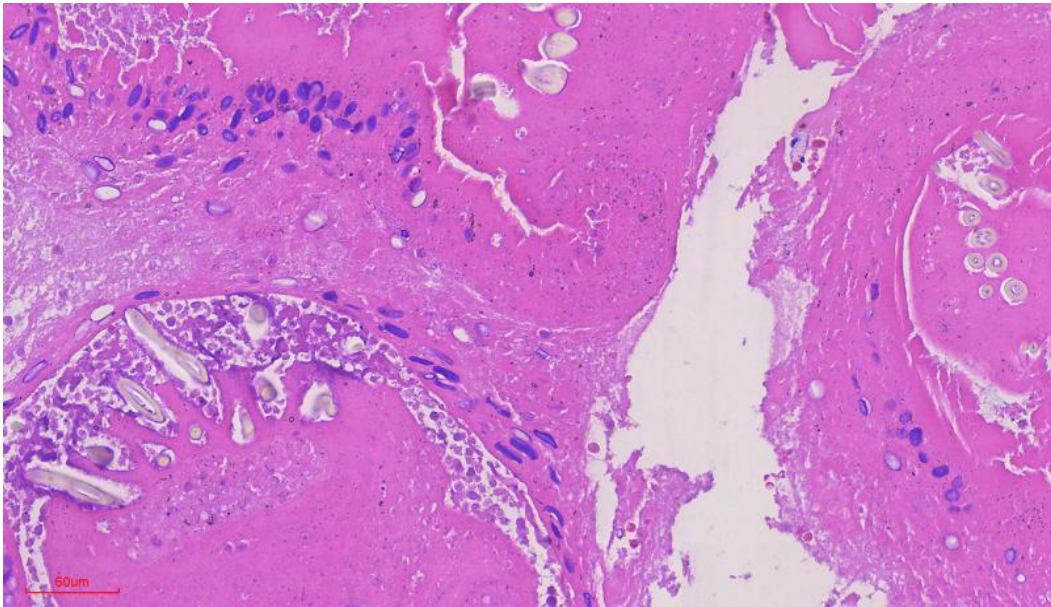
S. No	Age (years)	Sex	History	Tissue/Organ	Diagnosis
1	65	F	Recurrent left loin pain and features of distal left sided ureteric obstruction.	Ureter	Schistosomiasis
2	42	M	one week history of progressive inability to walk and urinary incontinence. Conus medullaris tumour.	Organism was not identified due to extensive calcification	Features suggest a parasitic infection
3	65	M	Urethral stricture. Had anastomotic urethroplasty	Urethra	Schistosomiasis
4	6	M	Sudden onset convulsion and hemoptysis	Brain	Parasitic cyst probably Neurocysticercosis.
5	64	M	Recurrent epigastric pains of 10 years with abdominal CT suggestive of tumour in the pancreas. Intra-operatively, there were multiple greyish white peritoneal and omental tumour swellings and a greyish white tumour on the lower pole of spleen.	Peritoneum	Schistosomiasis
6	50	M	Painless haematuria x 7 months and bladder mass at the left ureteric orifice.	Bladder	Non-Keratinizing Squamous Cell Carcinoma with Schistosomiasis
7	24	F	Progressively increasing mass on the left forearm for two months.	Forearm soft tissue	Cysticercosis
8	25	F	A 25-year-old girl with recurrent right iliac fossa pain.	Appendix	Schistosomiasis
9	29	M	Left loin pain of 4 months duration. Abdominopelvic ultrasound revealed left hydronephrosis and hydroureter with distal obstruction.	Ureter	Schistosomiasis
10	3	F	Painless anterior abdominal swelling of a week duration.	Soft tissue of anterior abdominal wall	Cysticercosis
11	23	M	Left occipital craniotomy with tumour resection on account of left occipital cystic lesion.	Brain	Cysticercosis



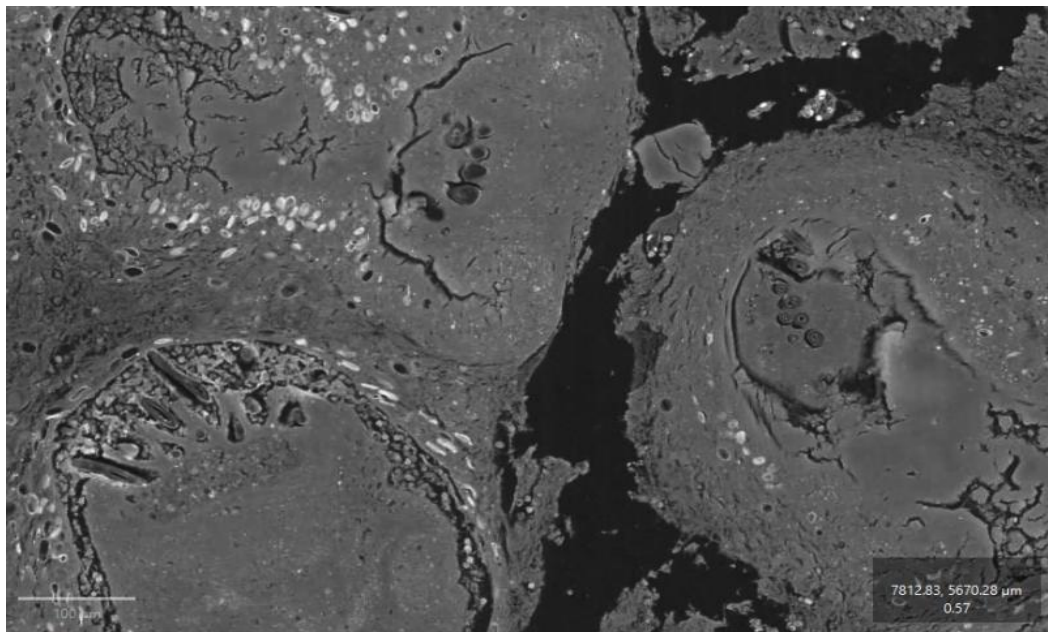
**Fig. 1.** The photomicrograph above is haematoxylin and eosin-stained section of the case of histoplasmosis of the bone. There are multinucleated giant cells with intracytoplasmic yeasts (black arrows). The yeasts were found to be positive for Gomori-Methenamine-Silver stain. The blue arrow points to the nuclei of multinucleated macrophages



**Fig. 2.** The photomicrograph above is residual colour deconvolution of a digitally scanned haematoxylin and eosin-stained section of the same tissue in Fig. 1 viewed using Qu Path software. The spherical structures that were whitish in Fig. 1 now appear dark while the dark nuclei of the multinucleated giant cells that were dark now appear whitish. The white arrow points to the yeasts while the brown arrow points to the nuclei of multinucleated macrophages



**Fig. 3.** The photomicrograph above is a haematoxylin and eosin-stained section of a cysticercosis of the brain showing the hooklets



**Fig. 4.** The photomicrograph above is residual colour deconvolution of a digitally scanned haematoxylin and eosin-stained section of the same tissue in Fig. 3 viewed using Qu Path software. The sectioned hooklets appear dark. This may be helpful in identifying the organism

## 4. DISCUSSION

### 4.1 Aspergillosis

The five cases of *Aspergillus* infection (three males and two females) found in our study was the highest frequency of fungal infections. This suggests it could be the most frequent cause of

morbidity from deep mycoses in patients. Even though only five cases were seen, it is known in this area that many patients do not seek medical attention in tertiary health centres due to lack of financial resources.

*Aspergillus* infection is a known complication of tuberculosis. Hence its presence in the lungs

following long term tuberculosis infection is not unusual. The destruction of the lung parenchyma by *Mycobacterium tuberculosis* is known to predispose the bronchial and pulmonary tissues to infection by fungal organisms. *Aspergillus spp* is quite ubiquitous in nature and more likely to complicate tuberculosis. It has been known to cause bronchopulmonary aspergillosis (BPA) and invasive aspergillosis.

Invasive pulmonary aspergillosis found in two cases in our study presented with cough, haemoptysis, and weight loss. These clinical features mimic a new or recurrent tuberculosis. It is important that patients with these symptoms are adequately investigated to ensure appropriate treatment. It also highlights the need to consider invasive aspergillosis in differential diagnosis of recurrent symptoms in patients treated for tuberculosis. This should be in addition to considering drug resistance or treatment failure.

Invasive aspergillosis of the bladder is not very common. The case we found in our study presented with passage of fleshy material per urethra. This makes it an important differential diagnosis in patients presenting with similar symptoms. Passage of fleshy material via the urethra, a common presentation of bladder cancer, should make a clinician suspicious of Invasive aspergillosis of the bladder especially in patients susceptible to the infection.

We identified a case of aspergillosis involving both breasts in a young woman. This was earlier diagnosed clinically as inflammatory carcinoma (a clinical presentation of invasive ductal carcinoma). This is quite a unique presentation that reinforces the need for thorough investigation of patients with the characteristic swollen breasts and *p'eau d'orange*. Making the diagnosis of aspergillosis can be quite difficult as trucut biopsies may show inflammatory reaction and fail to include the fungal hyphae that is necessary for definitive diagnosis of this condition. The importance of identifying this lesion cannot be overemphasized as wrong treatment with immunosuppressive drugs will likely worsen the patient's condition [17].

## 4.2 Mucormycosis

We found two cases of mucormycosis in our study, one case in a woman and one in a man. The cases presented as nasal obstruction with loss of vision, nasal blockage and discharge and

recurrent nasal discharge. Based on these findings, we suggest a high index of suspicion of mucormycosis in patients with nasal discharge or blockage that has been non-responsive to treatment or intractable. It was well known that many cases are due to underlying reduced immunity commonly due to diabetes mellitus. We found diabetes mellitus in one patient. It is possible that the other patient has other underlying immune deficiencies.

Nasal mucormycosis is an aggressive disease that can be fatal, especially in patients with diabetes mellitus. The only patient with mucormycosis with underlying diabetes mellitus was seen to have the most advanced form of the disease with loss of vision. There should be a high index of suspicion of mucormycosis in patients with nasal symptoms and underlying diabetes. Biopsy of lesions with fungal studies is important to rapidly identify this destructive infection that can rapidly cause neurological complications as seen in one of the patients.

## 4.3 Histoplasmosis

Thotan *et al* had earlier reported fungal infections mimicking a sarcoma [9]. In our study, we identified a single case of histoplasmosis in the humerus of a young man. This was clinically and radiologically diagnosed as a malignant bone tumour. This suggests that histoplasmosis of the bone can mimic bone tumours. Hence, a bone biopsy is required for confirmation before instituting a therapeutic regimen. The histologic section showed numerous giant cells and mimicked a giant cell tumour of the bone. Care should be taken as the fungal spherules may have a similar size to that of the nuclei of the multinucleated giant cells where they are found. The spherules can look like vesicular nuclei. It is important that histopathologists are made to be aware of this characteristic. Gomori-methenamine-silver stain can easily confirm the nature of the intracytoplasmic structures.

## 4.4 Schistosomiasis

We identified two cases of schistosomiasis of the ureter. One case was in a young male farmer. All the cases involving the ureter presented with symptoms of ureteric obstruction. The cause of the obstruction was only identified after histology of the biopsy. It is important to thoroughly investigate patients with upper urinary tract obstruction to rule out schistosomiasis as mere repair or removal of the obstruction may not be

sufficient in the management of the patients' condition. Many of the ova were found to be calcified.

We identified one case involving the urethra. The patient was an elderly man managed for urethral stricture. *Schistosoma* ova was identified after urethroplasty and biopsy. The clinical finding of urethral stricture, a disease condition more common in young males, in an elderly male is not very common. The stricture in this case was caused by fibrotic reaction generated by body reaction to the ova deposited in the periurethral tissues. It is necessary for urologic surgeons to send for histologic examination, all tissues excised during urethral repair to rule out schistosomiasis.

Urinary bladder is one of the main organs affected by schistosomiasis. Mendoza-Palomar *et al* in their review of imported schistosomiasis found the bladder to be a commonly involved organ. [12] We saw one case of schistosomiasis of the urinary bladder. This was in a middle-aged man with history of childhood hematuria. He presented with persistent hematuria. Cystoscopy was done and showed a bladder mass. We saw calcified ova likely of *Schistosoma haematobium* with a moderately differentiated squamous cell carcinoma. Squamous cell carcinoma is a well-known complication of the chronic irritation [18] caused by the presence of the ova in the bladder wall.

We identified one case each of schistosomiasis of the peritoneum and appendix. The case of schistosomiasis of the appendix presented with recurrent appendicitis while that of the peritoneum presented with a CT scan finding suggestive of intraabdominal tumour with multiple seedlings and was thought to likely be a pancreatic cancer. It is not unusual for schistosomiasis of the bladder to present with acute appendicitis [15]; however, it is quite uncommon to find a case presenting with multiple peritoneal seedlings. In our experience, multiple peritoneal nodules commonly suggest ovarian cancer (in women) or abdominal tuberculosis. Our finding suggests that schistosomiasis should be a differential diagnosis of multiple peritoneal seedlings.

#### 4.5 Cysticercosis

Cysticercosis is one of the most common parasitic infections of human tissues [19]. Cysticercosis was mainly found in young patients

with age range of 6-24 years. Two cases involved the brain while one case each involved the soft tissue of the arm and abdominal wall. The tumour masses had cystic areas when evaluated radiologically. All the cases were thought to be tumours prior to histologic diagnosis. It is important that clinicians consider the possibility of cysticercosis in all cases of cystic tumours particularly in young individuals. It is also important that neurosurgeons should have a high index of suspicion of neurocysticercosis in young patients with cystic intracranial mass. This will possibly minimize neurologic deficit that some patients may develop after resection of brain lesions as radical management may not be indicated in neurocysticercosis. It is also important to improve public health measures geared towards reducing parasitic infections as cysticercosis involving the brain can be very debilitating and cause serious morbidity.

It is necessary to note that all the parasitic diseases were accompanied by intense infiltration of the tissues by eosinophils and in many cases formation of granuloma with foreign body giant cells [20]. Hence presence of intense infiltration of trucut biopsy tissues by eosinophils even without the presence of ova of parasites or other forms should warrant efforts to look for parasites in the patients.

We could not conclusively identify a spinal cord lesion as the parasitic bodies were extensively calcified and our centre lack adequate ancillary techniques necessary for species determination. Some authors have earlier reported parasitic infections of the spinal cord by organisms like *Schistosoma spp* and *Taenia solium* [16]. It is necessary that we improve our facilities to better detect parasites for more specific management.

Many authors have studied the application of colour deconvolution, a method of digital stain separation, in histological images [21–23]. We observed a characteristic differential visualization of the foreign fungal and parasitic bodies when residual colour deconvolution is applied to the digital images of these organisms. This is shown in Figs. 1-4. This process of digital stain separation is fast, does not require reagents and could possibly be an added tool in identification of fungal and parasitic bodies in human tissues. This characteristic might be partly due to the inability of some of the structures in the fungi and parasite to take up either haematoxylin or eosin stain. However, a larger study is required to



ascertain its possible use in routine laboratory practice.

It is necessary to state that public health measures play a pivotal role in prevention of parasitic diseases. It is possible there are more lesions in the community that has not come to our attention and the scale of the problem is much more than we envisage.

## 5. CONCLUSION

Aspergillosis was the most diagnosed fungal infection while Schistosomiasis was the commonest parasitic infection. Aspergillosis of the breast can present with features of inflammatory carcinoma of the breast. Histoplasmosis of the bone can mimic a malignant tumour of the bone, particularly, a giant cell tumour of the bone. Schistosomiasis of the peritoneum should be among the differential diagnosis of patients with multiple peritoneal nodules and Schistosomiasis of the urethra in elderly males with urethral stricture. Cysticercosis maybe predominantly found in young patients. Digital stain separation by residual colour deconvolution of digital slides could possibly be an added to tool in identification of fungal and parasitic bodies.

## ETHICAL APPROVAL

As per international standard or university standard written ethical approval has been collected and preserved by the author(s).

## CONSENT

As per international standard or university standard, patient(s) written consent has been collected and preserved by the author(s).

## COMPETING INTERESTS

Authors have declared that no competing interests exist.

## REFERENCES

1. Bongomin F, Adetona Fayemiwo S. Epidemiology of fungal diseases in Africa: A review of diagnostic drivers. *Curr Med Mycol.* 2021;7(1):63–70.
2. Zeeshan M, Fatima S, Farooqi J, Jabeen K, Ahmed A, Haq A, et al. Reporting of mycetoma cases from skin and soft tissue biopsies over a period of ten years: A single center report and literature review from Pakistan. *PLOS Neglected Tropical Diseases.* 2022;16(7):e0010607.
3. Kwizera R, Bongomin F, Lukande R. Deep fungal infections diagnosed by histology in Uganda: a 70-year retrospective study. *Med Mycol.* 2020;58(8):1044–52.
4. Loubet D, Sarton B, Lelièvre L, Grouteau G, Iriart X, Chauvin P, et al. Fatal mucormycosis and aspergillosis coinfection associated with haemophagocytic lymphohistiocytosis: A case report and literature review. *J Mycol Med.* 2023;33(1):101325.
5. Bergantim R, Rios E, Trigo F, Guimarães JE. Invasive coinfection with *Aspergillus* and *Mucor* in a patient with acute myeloid leukemia. *Clin Drug Investig.* 2013; 33(Suppl 1):S51-55.
6. Safai Nodeh SR, Dehghan Manshadi SA, Jahanbin B, Khodaveisi S, Giasvand F, Seifi A, et al. Invasive fungal consecutive infections in a patient with acute myeloid leukaemia. *Nigerian Journal of Clinical Practice.* 2019;22(4):582.
7. Oladele RO, Osaigbovo II, Akanmu AS, Adekanmbi OA, Ekeng BE, Mohammed Y, et al. Prevalence of histoplasmosis among persons with advanced hiv disease, Nigeria. *Emerging Infectious Diseases Journal - CDC.* 2022;28:11. Available: [https://wwwnc.cdc.gov/eid/article/28/11/22-0542\\_article](https://wwwnc.cdc.gov/eid/article/28/11/22-0542_article)
8. Osaigbovo II, Oladele RO, Orefuwa E, Akanbi OA, Ihekweazu C. Laboratory diagnostic capacity for fungal infections in nigerian tertiary hospitals: A gap analysis survey. *West Afr J Med.* 2021;38(11): 1065–71.
9. Thotan SP, Kumar V, Gupta A, Mallya A, Rao S. Subcutaneous phycomycosis—fungal infection mimicking a soft tissue tumor: A case report and review of literature. *Journal of Tropical Pediatrics.* 2010;56(1):65–6.
10. Pacheco P, Ventura AS, Branco T, Gonçalves L, Carvalho C. Clinical experience in invasive fungal infections. *Clin Drug Investig.* 2013;33(Suppl 1): S23-26.
11. Paran Y, Ben-Ami R, Orlev B, Halutz O, Elalouf O, Wasserman A, et al. Chronic schistosomiasis in African immigrants in Israel. *Medicine [Baltimore].* 2019;98[52]: e18481.
12. Mendoza-Palomar N, Sulleiro E, Perez-Garcia I, Espiau M, Soriano-Arandes A,

- Martín-Nalda A, et al. Schistosomiasis in children: Review of 51 imported cases in Spain. *Journal of Travel Medicine*. 2020; 27(1):taz099.
13. Colley DG, Bustinduy AL, Secor WE, King CH. Human schistosomiasis. *Lancet*. 2014; 383[9936]:2253–64.
  14. Verjee MA. Schistosomiasis: Still a cause of significant morbidity and mortality. *Research and Reports in Tropical Medicine*. 2019;10:153–63.
  15. Haddad FA, Nutman T, Feldman DO, Correa M, Armas O, Haddad V, et al. 369. Tissue based species level molecular identification of schistosoma haematobium in appendiceal tissue. *Open Forum Infectious Diseases*. 2022;9(Supplement 2):ofac492.447.
  16. Majmundar N, Patel PD, Dodson V, Tran A, Goldstein I, Assina R. Parasitic infections of the spine: Case series and review of the literature. *Neurosurgical Focus*. 2019; 46(1):E12.
  17. Bongomin F, Ekeng BE, Kibone W, Nsenga L, Olum R, Itam-Eyo A, et al. Invasive fungal diseases in Africa: A critical literature review. *Journal of Fungi*. 2022; 8(12):1236.
  18. McManus DP, Dunne DW, Sacko M, Utzinger J, Vennervald BJ, Zhou XN. Schistosomiasis. *Nat Rev Dis Primers*. 2018;4(1):13.
  19. Choi WH, Chu JP, Jiang M, Lee YS, Kim BS, Kim DG, et al. Analysis of parasitic diseases diagnosed by tissue biopsy specimens at kyunghee medical center [1984-2005] in Seoul, Korea. *Korean J Parasitol*. 2010;48(1):85–8.
  20. Giorgio S, Gallo-Francisco PH, Roque GAS, Flóro e Silva M. Granulomas in parasitic diseases: The good and the bad. *Parasitol Res*. 2020;119(10): 3165–80.
  21. Zheng Y, Jiang Z, Zhang H, Xie F, Shi J, Xue C. Adaptive color deconvolution for histological WSI normalization. *Computer Methods and Programs in Biomedicine*. 2019;170.
  22. Pérez-Bueno F, Vega M, Sales MA, Aneiros-Fernández J, Naranjo V, Molina R, et al. Blind color deconvolution, normalization, and classification of histological images using general super Gaussian priors and Bayesian inference. *Computer Methods and Programs in Biomedicine*. 2021;211: 106453.
  23. Tadrous P. Digital stain separation for histological images. *Journal of Microscopy*. 2010;240:164–72.

© 2023 Olaofe et al.; This is an Open Access article distributed under the terms of the Creative Commons Attribution License (<http://creativecommons.org/licenses/by/4.0>), which permits unrestricted use, distribution, and reproduction in any medium, provided the original work is properly cited.

*Peer-review history:*

*The peer review history for this paper can be accessed here:*  
<https://www.sdiarticle5.com/review-history/101323>